

Effect of Reamer Design on Posteriorization of the Tibial Tunnel During Endoscopic Transtibial Anterior Cruciate Ligament Reconstruction

Sanjeev Bhatia,* MD, Kyle Korth,* BS, Geoffrey S. Van Thiel,* MD, MBA, Deepti Gupta,* BS, Brian J. Cole,* MD, MBA, Bernard R. Bach Jr,* MD, and Nikhil N. Verma,*[†] MD

Investigation performed at Rush University Medical Center, Chicago, Illinois

Background: It is known that small alterations in tunnel positioning during anterior cruciate ligament (ACL) reconstruction significantly affect ACL length and tensioning patterns as well as alter force vectors and joint kinematics.

Purpose: To compare the amount of inadvertent posteriorization of the ACL tibial tunnel anatomy during transtibial ACL femoral reaming in the “over-the-top” position with a full femoral reamer versus a half femoral reamer, in comparison to the native tibial ACL footprint. It is hypothesized that the half reamer will result in less distortion of tibial tunnel anatomy and improved anatomic footprint coverage. It is also hypothesized that the true center of the tibial ACL footprint lies more anterior than previously described.

Study Design: Controlled laboratory study.

Methods: Eight cadaveric knee specimens were securely fixed to a stationary table at 90° of flexion and neutral rotation. After removal of the anterior capsule and patella, native joint anatomy was precisely recorded with a digitizer accurate to 0.05 mm. Tibial and femoral tunnels were then drilled in the manner of transtibial ACL reconstructions using the optimal tibial starting point of 15.9 mm below the medial plateau and 9.8 mm posteromedial to the medial margin of the tibial tubercle. After the 11-mm tibial tunnel was drilled, femoral tunnels were first drilled with a 10-mm half-fluted reamer, followed by a 10-mm full reamer. Each tibial tunnel's location and geometry relative to the native ligamentous insertion sites and joint anatomy were digitized.

Results: Digitized measurements of ACL insertional anatomy demonstrated that the center of the native ACL tibial footprint was 2.0 ± 0.49 mm (range, 1.1–2.7 mm) anterior to the posterior aspect of the lateral meniscus' anterior horn. Use of the 10-mm full femoral reamer resulted in a tibial-articular aperture that had a posterior edge 4.35 mm more posterior ($P = .049$) and extra-anatomic ($P = .006$) than the footprint of the 10-mm half femoral reamer.

Conclusion: Half-fluted reamers may be more advantageous for femoral tunnel reaming with a more oblique transtibial approach, as they result in less posterior tibial tunnel expansion than full reamers, possibly leading to improved graft function. Based on the digitized anatomy, the center of the tibial attachment site is anterior to the posterior aspect of the lateral meniscus's anterior horn, which has been traditionally described as the anatomic center.

Clinical Relevance: Use of half-fluted reamers for transtibial femoral tunnel reaming could lead to more anatomic tunnel placement and possibly improved graft mechanics after transtibial single-bundle ACL reconstruction.

Keywords: ACL reconstruction; tibial tunnel; anatomic; transtibial; ACL injury; posteriorization; reamer design

Despite an improved understanding of anterior cruciate ligament (ACL) biomechanics over the past several decades, the optimal surgical technique for ACL reconstruction remains unclear, largely because no ACL reconstruction procedure has been shown to replicate exactly the biomechanics of the native ACL.^{6,9,19} Small alterations in femoral tunnel positioning significantly affect ACL length and tensioning patterns as well as alter force vectors and joint kinematics.^{1,2,11,14} Loh et al¹⁴ showed that grafts placed higher

on the femoral wall in ACL reconstruction—a less coronally oblique orientation—do not effectively resist rotatory loads as compared with grafts placed lower on the femoral wall. Decreased sagittal plane obliquity has also been implicated, predominantly because such an orientation less effectively opposes anterior translational loads as compared with the native ACL.^{1,3,5,13}

To date, much of the focus regarding anatomically reconstructing ACLs has been placed on more accurately re-creating the femoral ACL footprint; however, correct tibial tunnel position within the native tibial footprint may be equally critical.⁴ Posterior tibial tunnel placement will result in a graft that is more vertical in the sagittal plane compared with normal ligament anatomy. As noted

TABLE 1
Demographics of Knee Specimens (n = 8)

Category	Characteristic
No. left/right knees	4 right, 4 left
Age, y	
Mean \pm SD	47.2 \pm 5.6
Range	36-53
Sex, n (%)	
Male	6 (75)
Female	2 (25)

by Bedi and colleagues,⁴ a knee with an ACL graft placed in a tibial tunnel on the posterior aspect of the tibial footprint had no significant difference in anterior translation during Lachman and pivot-shift testing compared with an ACL-deficient knee.

During femoral tunnel preparation in the transtibial technique, a guide wire (Beath pin) is placed through the reamed tibial tunnel via an “over the top” femoral guide into its position on the femur.¹⁸ To remain anatomic on the femur, the guide pin is regularly placed posterolateral to the center of the tibial tunnel’s intra-articular aperture. Passing a femoral reamer through the tibial tunnel over the Beath pin in this position consistently removes several millimeters of bone from the posterolateral aspect of the tibial tunnel rim, in a trajectory defined by the guide wire’s position. To date, no study has quantified the amount and extent of posteriorization of the tibial tunnel during femoral reaming and its effect on the tibial insertional anatomy. The senior author uses a half-fluted reamer in this situation, which is passed into the joint without reaming, thus preserving the tibial tunnel articular aperture.

The purpose of this study is to compare the amount of inadvertent posteriorization of the ACL tibial tunnel anatomy during transtibial ACL femoral reaming in the over-the-top position with a full femoral reamer versus a half femoral reamer, in comparison to the native tibial ACL footprint. It is hypothesized that the half reamer will result in less distortion of tibial tunnel anatomy and improved anatomic footprint coverage, primarily because of its improved ability to navigate obliquely the tibial tunnel intra-articular aperture.

MATERIALS AND METHODS

Eight fresh-frozen adult knee specimens (mid thigh to mid knee, 4 right, 4 left) without ligamentous injury or significant degenerative joint disease were thawed over 24 hours. Demographic characteristics for the specimens are provided in Table 1. With care taken to preserve soft tissues about the knee joint, skin, muscle, and subcutaneous

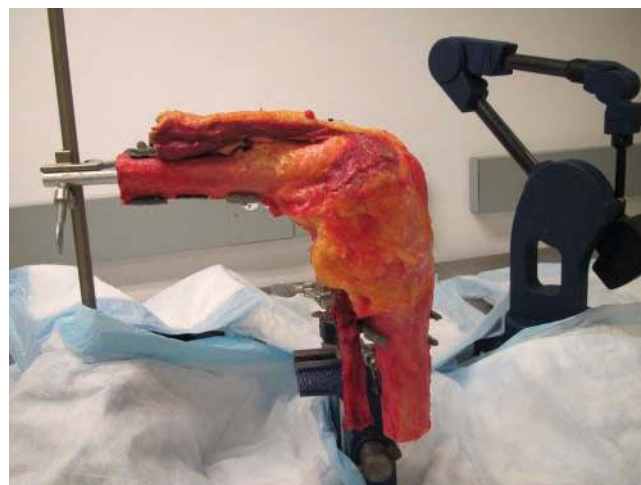

Figure 1. Specimens were mounted in 90° of flexion on a custom-designed mount stationary on a laboratory table stabilized to the floor.

tissue were removed from tibial and femoral diaphyses. Specimens were then mounted in 90° of flexion on a stationary custom-designed mount on a laboratory table stabilized to the floor (Figure 1). This flexion angle was chosen as it is the most common position of the knee during transtibial reconstruction techniques. To ensure that the necessary exposures of the ACL insertions did not destabilize the knee and result in aberrant motion of the tibia and femur, a 3-point coordinate system was arbitrarily defined on each specimen by choosing and marking a point on the femur, tibia, and laboratory table. As was done in previous studies¹⁸ with this equipment, the *x*, *y*, and *z* coordinates of each of these points were measured and repeatedly referenced throughout the study to ensure a static relationship between the femur, tibia, and digitizer (MicroScribe; CNC Services, Amherst, Virginia) accurate to 0.05 mm.

After the specimen was fixed on the custom-designed mount, the lateral femoral condyle was further secured to the lateral tibial plateau with 2 divergent K-wires. With the exception of the lateral collateral ligament and the posterior capsule, extra-articular soft tissues about the knee joint were then removed using sharp dissection, and the intact nature of the articular cartilage, meniscal attachments, and cruciate ligaments was confirmed. The superior border of the pes anserinus and anterior edge of the medial collateral ligament (MCL) were marked on the proximal tibia before removal.

To allow a post hoc 3-dimensional analysis, the knee joint’s femoral and tibial surface anatomy was then recorded using the digitizer to log extensive point cloud

[†]Address correspondence to Nikhil N. Verma, MD, Division of Sports Medicine, Department of Orthopaedic Surgery, Rush University Medical Center, 1611 West Harrison Street, Suite 201, Chicago, IL 60612 (e-mail: nverma@rushortho.com).

^{*}Division of Sports Medicine, Department of Orthopaedic Surgery, Rush University Medical Center, Chicago, Illinois.

Presented as a poster at the 38th annual meeting of the AOSSM, Baltimore, Maryland, July 2012.

One or more of the authors has declared the following potential conflict of interest or source of funding: Dr Verma has received research or institutional support and is a consultant or employee of Smith & Nephew. This study was funded by the Rush Department of Orthopaedic Surgery. Equipment, facilities, and personnel were also directly provided by the Rush Department of Orthopaedic Surgery. Certain testing equipment pertinent to the focus of this study was donated by Smith and Nephew (ACL reamers) and Synthes (K-wire driver).

arrays of both bones. In addition to articular surfaces and bony landmarks, soft tissue structures such as the anterior horn of the lateral meniscus, the medial meniscus, and the anterior face of the posterior cruciate ligament (PCL) at the posterior edge of the tibial plateau were fully digitized to better appreciate the anatomic relationship of the ACL to these structures.

With use of an oscillating saw, the medial femoral condyle was then carefully removed, with great precaution taken to avoid damage to the femoral ACL insertion—this was solely done to improve accuracy in digitizing the femoral ACL footprint using an en face view. The ACL was then sharply divided and removed with care to allow the tibial and femoral footprints to be digitized after being marked with a pen. The x , y , and z coordinates of the 3 arbitrary points on the tibia, femur, and laboratory were measured once again to confirm that the static relationship between the femur, tibia, and digitizer had not changed.

Surgical Technique

As recently described by Piasecki et al,¹⁸ there is an optimal tibial tunnel starting point (15.9 mm below the medial plateau, 9.8 mm posteromedial to the medial margin of the tibial tubercle) that best allows for anatomic femoral tunnel drilling using a transtibial technique. Using this tibial tunnel starting point, a guide pin was drilled using a standard ACL tibial tip aimer (Smith & Nephew Endoscopy, Andover, Massachusetts) to the center of the marked tibial footprint. The tibial tunnel was then reamed with an 11-mm cannulated reamer (Smith & Nephew Endoscopy) in standard fashion. Once reaming was complete, the intra-articular and extra-articular tibial tunnel apertures were carefully digitized to allow for tibial tunnel 3-dimensional mapping and measurement of the tunnel location in relation to the native ACL tibial and femoral footprint anatomy.

After tibial tunnel creation, a 7-mm offset aimer was inserted through the tibial tunnel and hooked around the posterior aspect of the intercondylar notch. To best achieve the over-the-top position, the aimer was placed in the posterolateral corner of the tibial tunnel and externally rotated to permit low pin position on the femoral notch's lateral wall. The center position of the native ACL femoral footprint had been previously marked, and the guide was rotated to allow placement of the pin at the center point of the native ligament. The anatomic center point of the femoral footprint was achieved in all specimens when the aimer was placed in the posterolateral corner of the tibial tunnel. Placing the aimer directly through the center of the tibial tunnel and not on the posterolateral corner of the tunnel consistently resulted in a nonanatomic or vertical femoral tunnel start point, one that was too anterior and too high on the notch (proximal).

A Beath pin was then inserted through the aimer and provisionally drilled through the native ACL femoral footprint center, exiting the lateral femoral cortex. A 10-mm half femoral reamer (Smith & Nephew Endoscopy) was then passed over the Beath pin while in the off position. Because the Beath pin was placed posterolateral to the center of the tibial tunnel's intra-articular aperture, the blades

of the half reamer were anteriorly positioned to navigate obliquely the tibial tunnel while in the off position (Figure 2D). Upon entering the joint and contacting the femur, the reamer was started, and a standard 10-mm tunnel was drilled to a depth of 25 mm. After femoral tunnel drilling, the half reamer was again turned off and removed by once again positioning the blades anteriorly to allow easier passage through the tibial tunnel to minimize change to the intra-articular aperture. The digitizer was once again used to record the tibial tunnel intra-articular aperture and tunnel location compared with the native anatomy.

After femoral reaming with a half reamer, a 10-mm full-fluted femoral reamer (Smith & Nephew Endoscopy) was then used in the same manner. However, because of the Beath pin's oblique position within the tibial tunnel, the full reamer's blades were unable to clear the intra-articular tibial tunnel aperture while in the off position (Figure 2B). The reamer was therefore turned on, resulting in the removal of several millimeters of bone from the posterolateral aspect of the tibial tunnel rim. After entrance into the joint, the reamer was easily positioned into the previously reamed femoral tunnel while off, confirming no change in trajectory with that of the half reamer. The tibial tunnel intra-articular aperture, now slightly wider and more oblong, was redigitized as done previously. The digitizer was also used to record the edges of the femoral tunnel on the lateral wall of the notch for comparison with the native ACL femoral footprint. A visual comparison of the half reamer and full-fluted reamer is shown in Figure 3.

Analysis

Several subsequent analyses were performed using the 3-dimensional point cloud arrays recorded with the digitizer. Rhino software (McNeel, Seattle, Washington) was used to determine geometrically the center of the native tibial footprint and measure in millimeters the anatomic relationship of this point with other anatomic structures. The software was also used to calculate the following: surface areas of the tibial tunnel aperture (both before and after use of the half reamer and full reamer in the femur), tibial tunnel length, center of tibial tunnel intra-articular aperture (before and after femoral reaming), and amount of tibial tunnel posteriorization after femoral reaming. The percentage overlap of the tibial tunnel surface area with that of the native tibial insertion was directly computed. Statistical analysis of continuous variable data was performed with t tests with alpha set to .05 using GraphPad Software (La Jolla, California); P values below this were deemed significant. Pre hoc sample size for comparison of tibial tunnel sizes was determined by a power analysis (G*Power 3.0, Dusseldorf, Germany). Assuming a 50% increase in tunnel size and a standard deviation of 0.25 as the mean value, to achieve a power of 0.80 with a 2-tailed analysis, 6 specimens were required.

RESULTS

All 8 knee specimens were observed to have intact cruciate ligaments and menisci as well as no significant degenerative

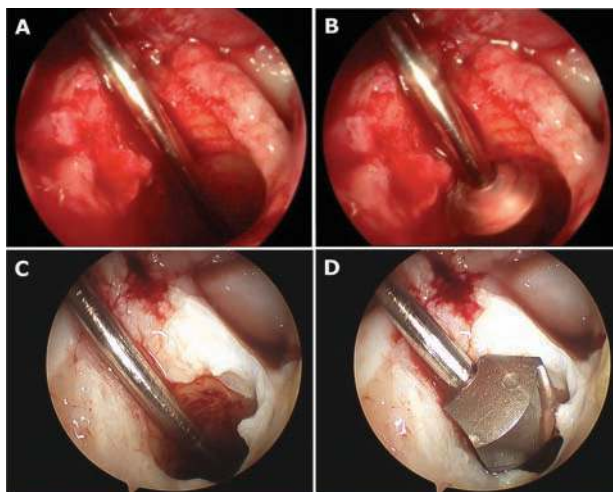


Figure 2. Comparison of a full- versus half-fluted femoral reamer during passage through the tibial tunnel intra-articular aperture before femoral transtibial reaming. (A) The 11-mm tibial tunnel with Beath pin aligned along posterolateral edge in the over-the-top position. (B) The 10-mm full-fluted femoral reamer. Note the reamer's inability to navigate obliquely the tibial tunnel while in the off position. To enter the joint, the reamer must be started; this in turn results in the removal of the posterior edge of the tibial tunnel aperture. (C) A different 11-mm tibial tunnel with the Beath pin aligned along the posterolateral edge in the over-the-top position. (D) The 10-mm half-fluted femoral reamer. The reamer's smaller width allows it to navigate obliquely the tibial tunnel while in the off position, resulting in less posterior expansion of the aperture.



Figure 3. A 10-mm full-fluted standard femoral reamer (top) versus 10-mm half-fluted reamer (bottom) used for transtibial femoral tunnel creation in the over-the-top position.

joint disease. In all testing situations for all specimens, the digitizer and 3-point coordinate system were used to reference the precise spatial orientation of the tibia and femur to ensure a static relationship between testing conditions, within 0.1 mm.

Digitized measurements of ACL insertional anatomy in the anteroposterior plane demonstrated that the center of the native ACL tibial footprint (combination of anteromedial and posterolateral bundle footprints) was 2.0 ± 0.49 mm (range, 1.1-2.7 mm) anterior to the posterior aspect of the lateral meniscus' anterior horn (Figure 4). Additional values

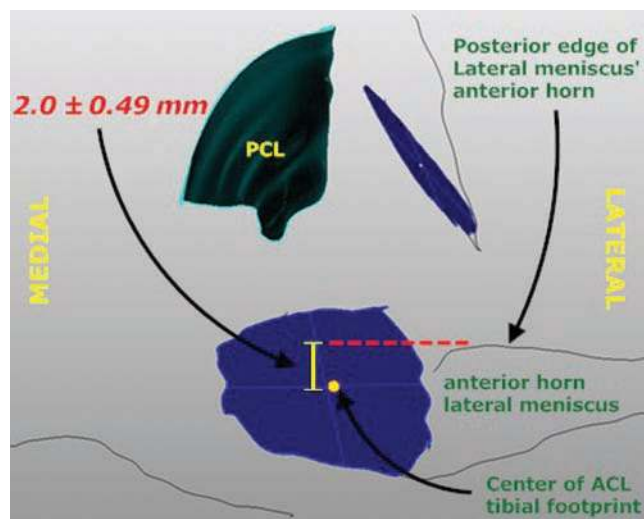


Figure 4. Anatomic relationship of the center of the native anterior cruciate ligament (ACL) tibial footprint (blue) and the posterior edge of the anterior horn lateral meniscus as seen in a typical anterior arthroscopic view of the knee. Note that the center of the native tibial ACL footprint is 2.0 ± 0.49 mm anterior to the posterior edge of the lateral meniscus' anterior horn in the anteroposterior plane, a value slightly more anterior than previously reported in some studies.^{12,15,16}

demonstrating the anatomic relationships of the ACL footprints to the anterior aspect of the lateral meniscus and the posterior aspect of the medial meniscus are provided in Table 2.

After the use of the 11-mm tibial reamer, the tibial tunnel length was found to be 32.07 ± 2.62 mm. The tibial-articular ACL footprint area was 111.45 ± 16.40 mm², compared with the native size of 151.53 ± 28.95 mm² (Table 3). Femoral reaming with the 10-mm half-fluted reamer centered on the femoral footprint with an over-the-top guide produced a tibial-articular ACL footprint of 120.29 ± 12.43 mm² but did not significantly increase the aperture of the tibial tunnel created during tibial reaming ($P = .24$). Repeated femoral reaming with the 10-mm full reamer centered on the femoral footprint in the same over-the-top trajectory produced a tibial tunnel intra-articular aperture surface area of 189.94 ± 22.13 mm², a value significantly larger than the initial tibial tunnel intra-articular aperture after 11 mm tibial reaming ($P < .0001$).

In comparing the location of the ACL tibial-articular footprint with relation to joint anatomy, distances from each landmark were found to vary as reaming progressed (Table 2). While the center of the native tibial footprint was digitized to be 18.03 ± 2.53 mm anterior to the PCL at the level of the tibial plateau (Figure 5), the center of the tibial footprint of the 10-mm half-fluted reamed tunnel measured 17.39 ± 5.06 mm anterior to the PCL. The 10-mm full-fluted reamed tibial tunnel footprint was further posterior, with a distance of 14.50 ± 3.59 mm anterior to the PCL. The distance from the posterior edge of the ACL tibial-articular footprint to the PCL at the tibial plateau was also measured

TABLE 2
Digitized Anatomic Relationships Observed (in mm) in the ACL Tibial-Articular Footprint^a

Footprint Center	PCL (Tibial Plateau)	Posterior Aspect: Lateral Meniscus, Anterior Horn	Anterior Aspect: Lateral Meniscus, Anterior Horn	Posterior Aspect: Medial Meniscus, Anterior Horn
Native	18.03 ± 2.53	7.53 ± 0.77	8.75 ± 0.53	11.55 ± 1.17
11-mm full tibial reamer ^b	17.90 ± 4.90	7.69 ± 3.31	8.14 ± 1.30	11.50 ± 3.56
10-mm half femoral reamer ^c	17.39 ± 5.06	7.70 ± 3.14	8.67 ± 1.27	11.82 ± 3.48
10-mm full femoral reamer ^c	14.50 ± 3.59	5.70 ± 1.42	10.17 ± 1.92	15.31 ± 2.45

^aDistance measurements listed are in the axial plane of the knee. ACL, anterior cruciate ligament; PCL, posterior cruciate ligament.

^bTunnels were reamed with the guide centered on the tibial-articular ACL footprint with no subsequent femoral reaming.

^cTunnels were reamed with the guide centered on the femoral-articular ACL footprint in the over-the-top position with subsequent femoral reaming.

to investigate the presence of posteriorization with femoral reaming. As shown in Table 4, use of the 10-mm full femoral reamer produced significant posteriorization of the ACL tibial-articular footprint, with a distance of only 6.31 ± 2.62 mm from the posterior edge of the footprint to the tibial plateau compared with 10.66 ± 4.57 mm for the half-reamed footprint ($P = .049$). Use of this full reamer resulted in posteriorization of the center of the tibial articular aperture by 5.44 ± 1.84 mm, which then produced a 59.62% ± 28.1% expansion of the tunnel area at the posterior surface ($P < .0001$ when compared with the aperture surface after femoral reaming with the half reamer).

When comparing the location of the reamed tibial tunnel aperture with the native ACL footprint, both the 10-mm full femoral reamer and the 10-mm half femoral reamer resulted in a similar percentage of native tibial ACL footprint overlap by the tibial intra-articular aperture (tunnel aperture area overlapping with footprint divided by ACL footprint total area; Table 5). However, when the area of the tibial aperture outside of the ACL native footprint was evaluated in relation to total tibial aperture area, the 10-mm full femoral reamer resulted in an aperture that was significantly more extra-anatomic than the 10-mm half femoral reamer ($P = .006$; Table 6).

Finally, the distance from the center of the ACL's tibial footprint to the posterior aspect of the lateral meniscus' anterior horn remained fairly constant from the native location (7.53 ± 0.77 mm) to the time of the 10-mm half reaming (7.70 ± 3.14 mm; Table 2). However, this distance decreased to 5.70 ± 1.42 mm when the full reaming of the femur was performed. The P value for comparison of the native location's distance to the same distance measured after full-fluted femoral reaming was $P = .001$ (paired t -test results).

These trends in posteriorization with subsequent reaming are depicted in Figure 6.

DISCUSSION

Through the use of a highly precise digitizer and analysis of spatial relationships, the findings of this study demonstrate that the true center of the native tibial ACL footprint may actually lie approximately 2 mm anterior to

TABLE 3
Surface Areas (in mm²) of Tibial Intra-articular Apertures Created After Tibial and Femoral Reaming

Measured Structure	Surface Area	P Value ^a
Native ACL tibial footprint	151.53 ± 28.95	—
11-mm full tibial reamer ^b	111.45 ± 16.40	—
10-mm half femoral reamer ^c	120.29 ± 12.43	.244
10-mm full femoral reamer ^c	189.84 (±22.13)	<.0001

^aCompared with the surface area of 11-mm tibial tunnel aperture.

^bTunnels were reamed with the guide centered on the tibial-articular ACL footprint with no subsequent femoral reaming.

^cTunnels were reamed with the guide centered on the femoral-articular ACL footprint in the over-the-top position with subsequent femoral reaming.

the posterior aspect of the anterior horn of the lateral meniscus. This suggests that previously recommended tibial tunnel positions^{12,15,16} in single-bundle ACL reconstruction may have been slightly too posterior. These results are corroborated by more recent reports on tibial tunnel footprint anatomy that also suggest a more anterior position.²² In addition, the findings of this study show that further posteriorization of the tibial tunnel intra-articular aperture may inadvertently occur from transtibial femoral tunnel reaming if a standard full-fluted reamer is used in the over-the-top position as opposed to a half reamer. In fact, this inadvertent posteriorization may result in a tibial tunnel intra-articular aperture that is significantly more extra-anatomic (a higher percentage of reamed aperture that is outside the boundaries of the native ACL footprint) than one produced by a half-fluted femoral reamer. Such distortion of the tibial tunnel intra-articular aperture occurs because a guide pin placed anatomically on the femoral ACL footprint is generally positioned posterolateral to the center of the tibial tunnel's intra-articular aperture. Full reamers, unable to navigate obliquely a tibial tunnel, require removal of bone at the posterolateral edge to allow entry to the joint and femoral tunnel creation. These reamers were unable to be introduced into the joint in the off position. Half reamers, in contrast, have a lower profile, which better optimizes navigation over the tibial tunnel edge when introduced by

TABLE 4
Posteriorization of Tibial Tunnel Posterior Lip (in mm)
After Femoral Reaming With Half Versus Full Reamer

Footprint Posterior Edge	Distance to PCL at Tibial Plateau	P Value ^a
11-mm full tibial reamer ^b	11.44 ± 4.56	—
10-mm half femoral reamer ^c	10.66 ± 4.57	.57
10-mm full femoral reamer ^c	6.31 ± 2.62	.049

^aCompared with the 11-mm tibial tunnel aperture.

^bTunnels were reamed with the guide centered on the tibial-articular ACL footprint with no subsequent femoral reaming.

^cTunnels were reamed with the guide centered on the femoral-articular ACL footprint in the over-the-top position with subsequent femoral reaming.

TABLE 5
Percentage of Native Tibial Footprint Overlapped
by Reamed Tibial Intra-articular Aperture^a

	11-mm Full ^b	10-mm Half ^c	10-mm Full ^c
Average	59.03 ± 15.35	64.75 ± 15.34	72.15 ± 9.79
P value (10-mm half vs full)		.31	

^aObtained by dividing the tunnel aperture area overlapping with footprint by the anterior cruciate ligament (ACL) footprint total area.

^bTunnels were reamed with the guide centered on the tibial-articular ACL footprint with no subsequent femoral reaming.

^cTunnels were reamed with the guide centered on the femoral-articular ACL footprint in the over-the-top position with subsequent femoral reaming.

TABLE 6
Percentage of Reamed Aperture That Is Outside
of the Native ACL Tibial Footprint^a

	11-mm Full ^b	10-mm Half ^c	10-mm Full ^c
Average	19.52 ± 22.99	19.23 ± 19.38	43.05 ± 7.58
P value (10-mm half vs full)		.006	

^aObtained by dividing the area of the tibial aperture outside of the anterior cruciate ligament (ACL) native footprint by the total tibial aperture area.

^bTunnels were reamed with the guide centered on the tibial-articular ACL footprint with no subsequent femoral reaming.

^cTunnels were reamed with the guide centered on the femoral-articular ACL footprint in over-the-top position with subsequent femoral reaming.

hand in the off position. Thus, the half reamers are more easily able to slide into the joint manually while in the off position, whereas the full reamers generally require

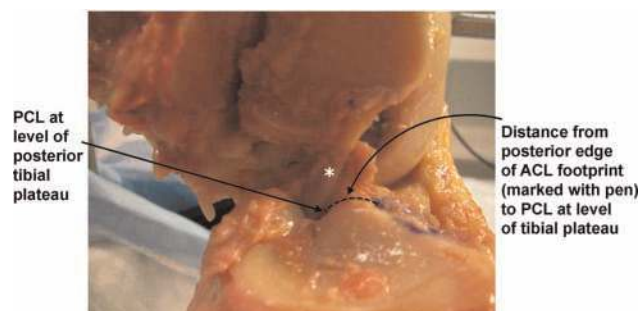


Figure 5. Visual depiction of how the distance from the posterior edge of the anterior cruciate ligament footprint to the posterior cruciate ligament (*) at the level of tibial plateau was digitized.

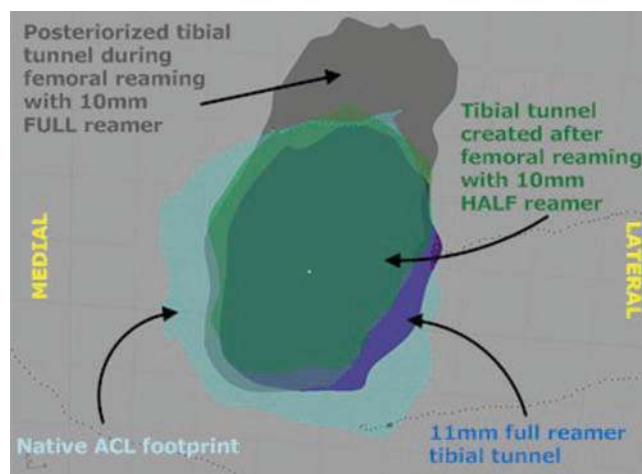


Figure 6. Native tibial anterior cruciate ligament footprint (light blue) in the left knee with an outline of tibial tunnels created using various reamers. Note the posteriorization of the tibial tunnel footprint during femoral reaming with the 10-mm full reamer.

a transient amount of power to remove obstructing bone on the posterior aspect of the tibial tunnel.

As understanding of ACL biomechanics and kinematics continues to advance, the need for anatomic tunnel placement during ACL reconstructive surgery is increasingly being recognized.^{4,8,18,21} While much attention thus far has been directed toward modifying surgical techniques for more properly creating femoral tunnels, techniques and descriptions for precise and accurate tibial tunnel placement remain poorly defined. Posteriorization of the tibial tunnel results in a vertical graft in the sagittal plane with subsequent loss of function. The findings of this study demonstrate that use of a standard reamer for femoral tunnel drilling during transtibial ACL reconstruction results in significant expansion and posteriorization of the tibial tunnel articular aperture as compared with a half-fluted femoral reamer and native ACL footprint anatomy.

The modified transtibial ACL reconstruction technique has been demonstrated to have equal efficacy in improving knee joint biomechanical stability as ACL reconstructions performed via an anteromedial portal technique and an outside-in technique. Sim et al²⁰ performed a controlled laboratory study using a robotic testing system to place uniform anteroposterior loads on cadaveric knees with reconstructed ACLs using one of three endoscopic approaches. The authors concluded that the modified transtibial technique, the anteromedial portal technique, and the outside-in technique were biomechanically comparable in restoring normal knee joint laxity and in situ ACL forces.²⁰ Such findings confirm the utility of the modified transtibial approach, assuming anatomic placement of femoral and tibial tunnels.

However, difficulty with precise tibial tunnel positioning within the native tibial footprint is compounded by the large shape of the tibial footprint, reported by some to be 3.5 times larger in area than the midsubstance cross-sectional area of the ACL.¹⁰ Because of this large shape, various arthroscopic landmarks such as the PCL or anterior horn of the lateral meniscus have been used for proper tibial tunnel positioning, particularly in the sagittal plane.^{7,12,15-17} As noted in some anatomic studies, the recommended position for the center of the tibial tunnel during single-bundle ACL reconstruction is in line with the posterior aspect of the lateral meniscus or 7 mm anterior to the femoral PCL attachment, a finding that may in fact be too posterior.^{12,15,16,22}

Excessive posteriorization of tibial tunnel position in ACL reconstruction procedures has been demonstrated to weaken significantly the biomechanical stability of the knee joint. Bedi and colleagues,⁴ in a cadaveric study investigating the effect of tibial tunnel position on knee kinematics and stability, performed ACL reconstruction in 10 paired cadaveric knees. The testing protocol involved varying the tibial tunnel position in the sagittal plane while keeping the femoral tunnel position constant. Using a computer navigation system to record the 3-dimensional motion during standardized Lachman testing, the authors found that a knee with a tibial tunnel placed in the posterior aspect of the tibial ACL footprint was no different from an ACL-deficient knee during Lachman testing.⁴ Anterior translation of the tibia during standardized pivot-shift testing was also significantly higher in knees with posteriorized tibial tunnels in comparison with constructs with more anterior tunnels.⁴ The authors concluded that the anterior positions for tibial tunnel placement are more effective in controlling anteroposterior translation during the Lachman testing and pivot-shift but must be balanced against an increased risk of graft impingement.

It is possible that poor biomechanics seen in ACL-reconstructed knees with posteriorized tibial tunnels may in part be explained by increased sagittal plane vertical orientation of the graft. By posteriorizing the tibial tunnel center, the tibial tunnel intra-articular aperture is brought closer to the femoral footprint, thereby reducing sagittal plane obliquity. Increased verticality of ACL grafts resulting from flawed tunnel creation has consistently been associated with poor outcomes and altered ACL force vectors. Loh et al¹⁴ showed that grafts placed higher on the femoral wall in ACL

reconstruction—a less coronally oblique orientation—less effectively resists rotatory loads as compared with grafts placed lower on the femoral wall. More recently, decreased sagittal plane obliquity has also been implicated, predominantly because such an orientation less effectively and less efficiently opposes anterior translational loads as compared with the native ACL.^{1,3,5,13}

The primary strength of this study is the precise digitization—accurate to 0.5 mm—of tibial tunnel anatomy and posteriorization after tibial tunnel reaming. This is the first time such technology has been applied in such a manner to identify tibial tunnel relationships. Moreover, tibial tunnel lengths in this study were noted to be consistent with tunnel lengths in other published studies,¹⁸ further validating proper tunnel placement and anatomic reconstruction technique employed in this study. Regarding limitations, the study's controlled laboratory study design using cadaveric specimens inherently restricts our ability to draw in vivo conclusions regarding the effects of tunnel posteriorization. In addition, it should be noted that the results reported were based on a tibial tunnel size of 11 mm and a femoral tunnel size of 10 mm, standard tunnels used during bone-patellar tendon graft ACL reconstruction. Given the widespread use of this graft choice, these tunnel sizes were chosen for this study. It is possible that smaller tibial and femoral tunnels would have resulted in a different degree of posteriorization noted. However, given the noncollinear nature of the tibial and femoral tunnels as well as the obliquity required by the femoral reamer in order to remain anatomic, posteriorization of the intra-articular tibial aperture would still have been likely to occur. Finally, given the static nature of our testing apparatus, the medial femoral condyle and MCL were removed to allow for more accurate digitization of the femoral ACL footprint using an en face view. Although great care was taken to stabilize the knee with multiple fixation points, it is possible, although highly unlikely, that subtle changes in joint positioning could have affected results. Given the anatomic nature of tibial tunnel placement, it is unlikely that removal of the medial femoral condyle artificially improved our ability to place the femoral tunnel accurately.

Posteriorization of the tibial tunnel often occurs inadvertently during ACL reconstruction. Using a half-fluted femoral reamer instead of a full-fluted femoral reamer may be more advantageous when performing ACL reconstruction using a transtibial technique, as this allows the reamer to navigate more easily the tibial tunnel through which it is passing obliquely. Other methods for minimizing tibial tunnel aperture bone loss may include introducing the femoral reamer transtibially without the use of a guide pin (and then placing a guide pin anatomicallly on the femur once the reamer is in the joint) or using an accessory medial portal for reaming of the femoral tunnel.

CONCLUSION

The anatomic center of the ACL tibial footprint lies 2 mm anterior to the posterior edge of the anterior horn lateral

meniscus. Half-fluted femoral reamers may be more advantageous than full-fluted femoral reamers when performing a single-bundle ACL reconstruction using a trans-tibial technique as they result in more anatomic tunnel placement with significantly less posteriorization of the tibial tunnel intra-articular aperture.

REFERENCES

1. Abebe ES, Kim JP, Utturkar GM, et al. The effect of femoral tunnel placement on ACL graft orientation and length during in vivo knee flexion. *J Biomech*. 2011;44(10):1914-1920.
2. Abebe ES, Moorman CT III, Dziedzic TS, et al. Femoral tunnel placement during anterior cruciate ligament reconstruction: an in vivo imaging analysis comparing transtibial and 2-incision tibial tunnel-independent techniques. *Am J Sports Med*. 2009;37(10):1904-1911.
3. Abebe ES, Utturkar GM, Taylor DC, et al. The effects of femoral graft placement on in vivo knee kinematics after anterior cruciate ligament reconstruction. *J Biomech*. 2011;44(5):924-929.
4. Bedi A, Maak T, Musahl V, et al. Effect of tibial tunnel position on stability of the knee after anterior cruciate ligament reconstruction: is the tibial tunnel position most important? *Am J Sports Med*. 2011;39(2):366-373.
5. Brophy RH, Pearle AD. Single-bundle anterior cruciate ligament reconstruction: a comparison of conventional, central, and horizontal single-bundle virtual graft positions. *Am J Sports Med*. 2009;37(7):1317-1323.
6. Bush-Joseph CA, Hurwitz DE, Patel RR, et al. Dynamic function after anterior cruciate ligament reconstruction with autologous patellar tendon. *Am J Sports Med*. 2001;29(1):36-41.
7. Chhabra A, Starman JS, Ferretti M, Vidal AF, Zantop T, Fu FH. Anatomic, radiographic, biomechanical, and kinematic evaluation of the anterior cruciate ligament and its two functional bundles. *J Bone Joint Surg Am*. 2006;88(suppl 4):2-10.
8. Colombet P, Robinson J, Christel P, Franceschi JP, Djan P. Using navigation to measure rotation kinematics during ACL reconstruction. *Clin Orthop Relat Res*. 2007;454:59-65.
9. Georgoulis AD, Ristanis S, Chouliaras V, Moraiti C, Stergiou N. Tibial rotation is not restored after ACL reconstruction with a hamstring graft. *Clin Orthop Relat Res*. 2007;454:89-94.
10. Harner CD, Baek GH, Vogrin TM, Carlin GJ, Kashiwaguchi S, Woo SL. Quantitative analysis of human cruciate ligament insertions. *Arthroscopy*. 1999;15(7):741-749.
11. Hefzy MS, Grood ES. Sensitivity of insertion locations on length patterns of anterior cruciate ligament fibers. *J Biomech Eng*. 1986;108(1):73-82.
12. Hutchinson MR, Bae TS. Reproducibility of anatomic tibial landmarks for anterior cruciate ligament reconstructions. *Am J Sports Med*. 2001;29(6):777-780.
13. Li G, Moses JM, Papannagari R, Pathare NP, DeFrate LE, Gill TJ. Anterior cruciate ligament deficiency alters the in vivo motion of the tibiofemoral cartilage contact points in both the anteroposterior and mediolateral directions. *J Bone Joint Surg Am*. 2006;88(8):1826-1834.
14. Loh JC, Fukuda Y, Tsuda E, Steadman RJ, Fu FH, Woo SL. Knee stability and graft function following anterior cruciate ligament reconstruction: comparison between 11 o'clock and 10 o'clock femoral tunnel placement. 2002 Richard O'Connor Award paper. *Arthroscopy*. 2003;19(3):297-304.
15. McGuire DA, Hendricks SD, Sanders HM. The relationship between anterior cruciate ligament reconstruction tibial tunnel location and the anterior aspect of the posterior cruciate ligament insertion. *Arthroscopy*. 1997;13(4):465-473.
16. Morgan CD, Kalman VR, Grawl DM. Definitive landmarks for reproducible tibial tunnel placement in anterior cruciate ligament reconstruction. *Arthroscopy*. 1995;11(3):275-288.
17. Petersen W, Zantop T. Anatomy of the anterior cruciate ligament with regard to its two bundles. *Clin Orthop Relat Res*. 2007;454:35-47.
18. Piasecki DP, Bach BR Jr, Espinoza Orias AA, Verma NN. Anterior cruciate ligament reconstruction: can anatomic femoral placement be achieved with a transtibial technique? *Am J Sports Med*. 2011;39(6):1306-1315.
19. Ristanis S, Giakas G, Papageorgiou CD, Moraiti T, Stergiou N, Georgoulis AD. The effects of anterior cruciate ligament reconstruction on tibial rotation during pivoting after descending stairs. *Knee Surg Sports Traumatol Arthrosc*. 2003;11(6):360-365.
20. Sim JA, Gadikota HR, Li JS, Li G, Gill TJ. Biomechanical evaluation of knee joint laxities and graft forces after anterior cruciate ligament reconstruction by anteromedial portal, outside-in, and transtibial techniques. *Am J Sports Med*. 2011;39(12):2604-2610.
21. Zantop T, Diermann N, Schumacher T, Schanz S, Fu FH, Petersen W. Anatomical and nonanatomical double-bundle anterior cruciate ligament reconstruction: importance of femoral tunnel location on knee kinematics. *Am J Sports Med*. 2008;36(4):678-685.
22. Ziegler CG, Pietrini SD, Westerhaus BD, et al. Arthroscopically pertinent landmarks for tunnel positioning in single-bundle and double-bundle anterior cruciate ligament reconstructions. *Am J Sports Med*. 2011;39(4):743-752.