

Technical Note

The Docking Technique for Posterolateral Corner Reconstruction

Nikhil N. Verma, M.D., Kai Mithöfer, M.D., Michael Battaglia, M.D., and John MacGillivray, M.D.

Abstract: Posterolateral corner injuries of the knee are an uncommon but potentially debilitating injury. They are easily missed on physical examination and are often associated with alternate ligament pathology. When identified early, these injuries are best managed by primary repair with or without augmentation of the involved structures. However, chronic injuries are generally not amenable to primary repair and often require reconstruction. Experimental data suggest that the lateral collateral ligament and popliteofibular ligament present critical biomechanical restraints of the posterolateral aspect of the knee and should be incorporated into contemporary reconstruction techniques. We describe a novel method of reconstructing these critical components of the posterolateral corner using a new docking technique for fixation on the femur with a graft placed through a fibular head tunnel. **Key Words:** Posterolateral corner—Ligament—Reconstruction—Allograft—Knee.

High-grade posterolateral corner injuries of the knee are rare but potentially devastating injuries. When untreated, it has been shown that these injuries result in persistent instability and progressive articular cartilage damage.¹ Acute high-grade injuries can be successfully treated with direct repair with or without augmentation.^{2,3} However, in patients with symptomatic chronic posterolateral instability, primary repair is rarely successful and reconstruction is recommended.^{4,5}

Because of the anatomic variability of the posterolateral corner⁶ and inconsistent combination of injured structures, multiple surgical techniques have been described for its reconstruction.^{3-5,7,8} Published biomechanical data have shown the critical importance of

the lateral collateral ligament (LCL) and the popliteofibular ligament (PFL) for resisting, posterior translation, varus opening, and external rotation.^{9,10} Given the biomechanical importance of these anatomic structures, it has been recommended that surgical reconstruction techniques should attempt functional restoration of the LCL and PFL.^{10,11} Based on previous techniques for anatomic reconstruction of the posterolateral corner used at our institution,¹² we have developed a new technique that uses an allograft tendon placed through a tunnel in the fibular head and a unique docking technique to accomplish fixation of the graft at the femoral epicondyle.

SURGICAL TECHNIQUE

The patient is placed on the table in a supine position. Once adequate anesthesia has been achieved, a thorough examination is conducted. Stability of the knee should be evaluated using Lachman, posterior drawer, pivot-shift, and varus/valgus testing. The posterolateral drawer should be performed and compared with the opposite side. Finally, external rotation spin

From the Sports Medicine and Shoulder Service, The Hospital for Special Surgery, Affiliated with the New York Hospital, Cornell University Medical Center, New York, New York, U.S.A.

Address correspondence and reprint requests to John MacGillivray, M.D., 535 E. 70th St, New York, NY 10021, U.S.A. E-mail: macgillivrayj@hss.edu

© 2005 by the Arthroscopy Association of North America
0749-8063/05/2102-4194\$30.00/0
doi:10.1016/j.arthro.2004.09.030

should be evaluated at 30° and 90° of knee flexion and compared with the opposite side.

Once the presence of a posterolateral corner injury has been confirmed, the tourniquet is inflated and the skin incision is marked out with the knee flexed approximately 30° over a bump. The lateral epicondyle is palpated and marked along with the fibular head. The incision should begin proximal and just posterior to the lateral epicondyle, curving posteriorly with the bend of the knee, and ending just distal and proximal to the fibular head. With the knee in full extension, the incision should form a straight line.

The incision is made and carried down to the underlying fascia and iliotibial band. Skin and subcutaneous tissue flaps are raised both anteriorly and posteriorly to allow for adequate visualization of the lateral epicondyle and posterior aspect of the biceps muscle belly and fibular head.

Next, the peroneal nerve should be identified and protected. The nerve is most easily visualized proximally, just posterior to the muscle belly of the biceps femoris. Once the nerve is identified, it is dissected distally as it passes across the fibular neck and enters the peroneal muscle belly. A vessel loop is passed around the nerve for its identification and protection throughout the remainder of the reconstruction.

Once the nerve has been isolated, the anterior and posterior borders of the fibular head are exposed subperiosteally using a combination of electrocautery and a periosteal elevator. A guidewire is then passed from anterior to posterior through the fibular head while using a broad periosteal elevator to protect the nerve posteriorly. Care must be taken to assure that the guidewire is placed medially to prevent lateral cortical fracture with subsequent reaming. A bone-block sizing guide from an anterior cruciate ligament reconstruction system can then be used as a soft-tissue protector as the guidewire is over-reamed with a 7- or 8-mm reamer. Finally, a No. 5 Ethibond suture (Ethicon, Somerville, NJ) is passed through the tunnel for later graft passage.

At this point, the lateral epicondyle of the femur is identified by direct palpation. The overlying iliotibial band is then incised for approximately 3 to 4 cm directly over this point. Blunt dissection allows visualization of the underlying remnants of the LCL and popliteal tendon, which will confirm proper identification of the isometric point. The remnants should be preserved as augmentation of the reconstruction. Subperiosteal dissection is carried out along the isometric point, and a slotted guide pin is drilled across the distal femur starting at the lateral epicondyle (Fig 1).

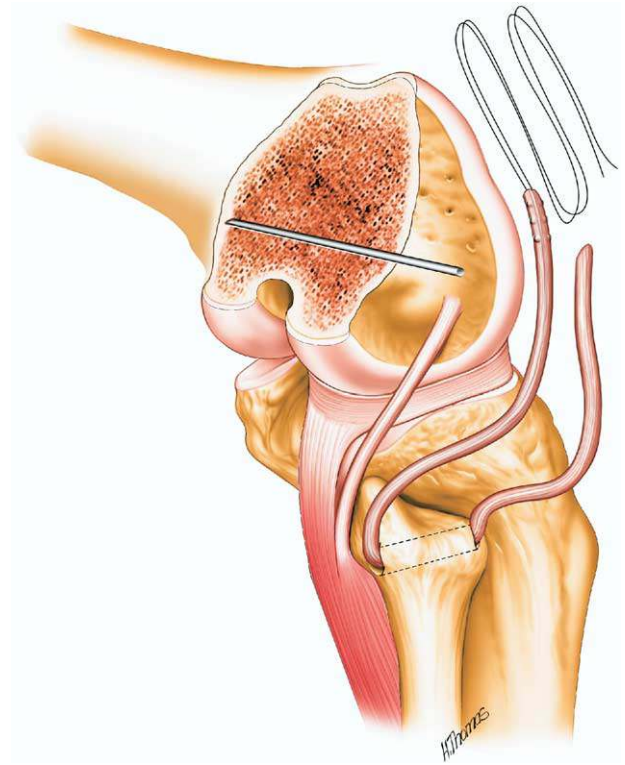


FIGURE 1. Guidewire placement in the lateral femoral epicondyle for drilling of the femoral tunnel. The pin is placed parallel to the knee joint and perpendicular to the shaft of the femur. It is drilled out the medial side of the knee percutaneously for later suture passage.

The pin should be parallel to the axis of the joint and perpendicular to the axis of the femur. It is brought out the medial side of the knee percutaneously.

We prefer to use allograft tissue for posterolateral corner reconstruction. Graft options include hamstring, Achilles tendon, or anterior tibial tendon allograft. One end of the graft is prepared by placing a No. 2 Fiberwire (Arthrex, Naples, FL) suture in a Krackow-type fashion. The opposite end of the graft is left free for later measurement once initial graft passage is complete.

At this point, the guidewire is overdrilled with an 8-mm reamer creating a 30-mm blind tunnel. Two No. 5 Ethibond passing sutures are then passed through the tunnel and out the medial side of the knee using the slotted guidewire. The graft is brought to the operative field and is passed through the fibular tunnel using the passing suture. A large Kelly clamp is then used to create a tunnel under the iliotibial band through which both limbs of the graft are passed.

Next, the limb of the graft that had sutures already

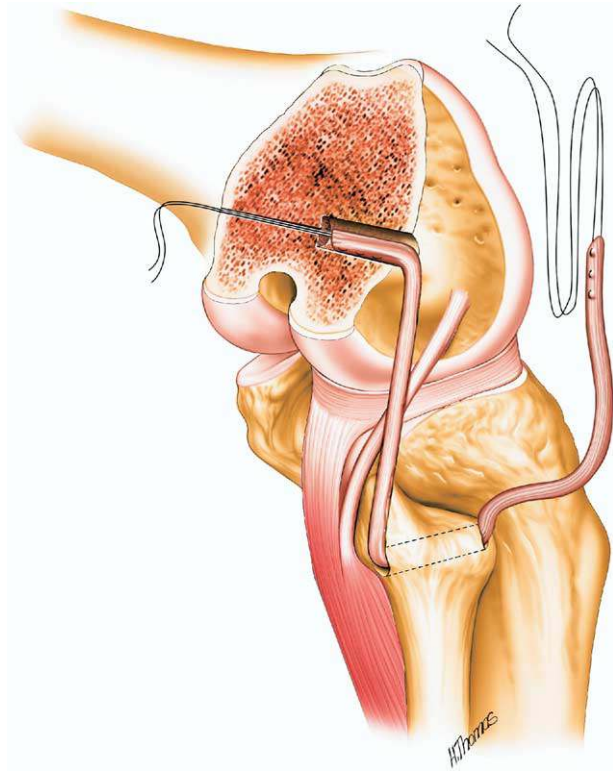


FIGURE 2. Graft passage: Both limbs of the graft have been tunneled underneath the overlying iliotibial band. The anterior limb has been passed into the femoral tunnel using the passing sutures. The posterior limb has been measured and marked and a Krackow stitch has been placed.

placed is passed into the femoral tunnel using 1 of the passing sutures (Fig 2). With this limb of the graft securely docked within the tunnel, the knee is reduced with internal rotation and valgus stress and taken through a range of motion to eliminate potential creep within the graft. The final length of the graft is estimated by placing the free limb of the graft next to the tunnel and estimating the length of graft that is required for proper tensioning within the femoral tunnel. This point is marked and a No. 2 Fiberwire suture is placed in Krackow-type fashion starting at this point and extending proximally. The excess portion of the graft immediately distal to the Krackow stitch is then sharply removed.

Finally, the end of the graft is securely docked within the femoral tunnel using the remaining passing stitch (Fig 3). As both ends of the graft are tensioned, the knee is taken through a gentle range of motion, and the graft is visualized to confirm isometry. The knee is then placed in approximately 20° of flexion, with internal rotation and slight valgus. The construct

is fixed with an interference screw in the femoral tunnel and supplemented with a button tied over the medial cortex through a separate small incision. The 2 limbs of the graft can be sutured together as they exit the femoral tunnel as necessary to augment tension. The incision is closed in the standard fashion.

DISCUSSION

Posterolateral corner injuries of the knee are uncommon and often associated with other ligament injuries.^{3,5} If left untreated, there is a high incidence of persistent disability from recurrent instability and accelerated degenerative cartilage changes.¹ Furthermore, failure to recognize an associated posterolateral complex injury can lead to early failure of intra-articular cruciate ligament reconstruction.¹³⁻¹⁵

Treatment of posterolateral corner injuries is based on the grade of the injury. For low-grade injuries, conservative management has been shown to be ef-

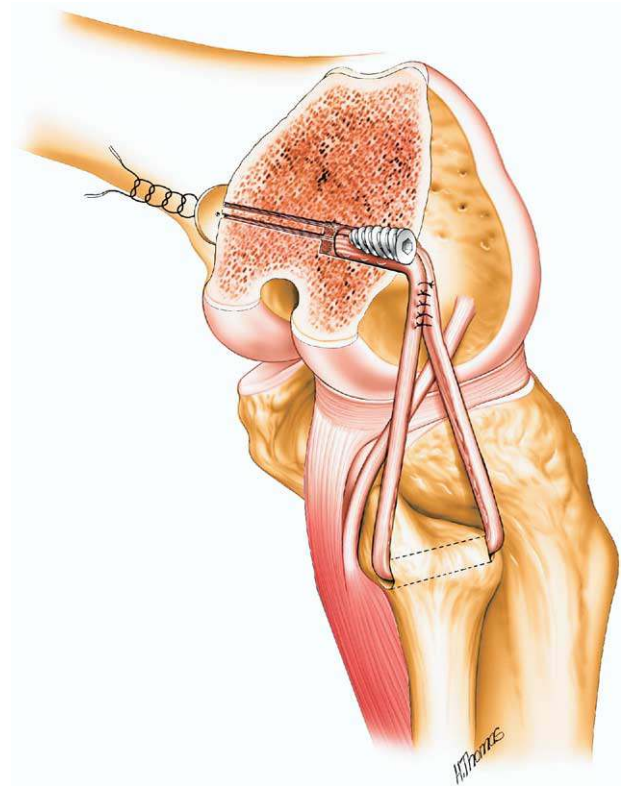


FIGURE 3. Passage of the posterior limb of the graft: The posterior limb of the graft has been “docked” in the femoral tunnel and both limbs are tensioned using the sutures from the medial side of the knee. The graft is then secured with an interference screw in the femoral tunnel and augmented with a button tied over the medial femur.

fective.¹ However, for grade III injuries with complete disruption of the lateral ligament complex and gross instability in varus and external rotation, conservative treatment has been reported to have poor results.¹ Although the natural history of these injuries has not been clearly delineated, biomechanical data and some limited follow-up studies have reported increased contact pressures in the medial and patellofemoral compartments with early degenerative changes.¹⁶ Therefore, the current recommendation for high-grade posterolateral corner injuries is surgical repair or reconstruction.¹⁷ In general, acute injuries treated with primary repair have more favorable outcomes than chronic injuries treated with reconstruction. Injuries identified early should be addressed within 3 weeks to avoid scar tissue formation that may make primary repair more difficult or impossible. Finally, associated ligamentous injuries must also be addressed at the time of repair or reconstruction.¹⁷

Many different techniques for reconstruction have been described for reconstruction of chronic posterolateral instability.^{4,5,7} When choosing which reconstruction to perform, biomechanical studies can be helpful in identifying which structures are most important to re-establish stability.

Selective sectioning studies have shown that the LCL, PFL, and tibial attachment of the popliteal tendon are all important in preventing excessive varus opening, external rotation, or posterior translation.^{9,10,12} All 3 of these structures must be compromised before marked increases in abnormal motion are noted. Furthermore, it has been shown that reconstruction of both the LCL and PFL will limit primary varus, posterior translation, and external rotation.^{12,18} Therefore, it has been postulated that reconstruction of the posterolateral corner should restore the function of these 2 important structures.^{9,12,18}

One major advantage of our technique for reconstruction of the posterolateral corner is the ease with which it can be performed. We prefer to use allograft tissue for our reconstructions because of the decreased morbidity of avoiding autograft harvest, such as biceps weakness,¹⁹ and the increased speed with which the reconstruction can be performed. Given that these injuries often involve multiple ligaments, the posterolateral reconstruction is often only part of a much longer and more complicated procedure. Decreased operative time may help to decrease the risk of perioperative complications such as infection or risks associated with the prolonged use of a tourniquet. Furthermore, allograft tissue has been used extensively in knee reconstruction, with excellent results. Our pri-

mary graft choices include hamstring or anterior tibialis tendon.

The docking technique has been described for medial collateral ligament reconstruction of the elbow.²⁰ We have adapted the concept of this technique for surgical reconstruction of the posterolateral corner. The anterior band of the graft recreates the LCL while the posterior band recreates the PFL. Both ends of the graft are then tensioned and fixed within a single femoral tunnel that can be placed at the lateral epicondyle. The grafts are then easily secured with a soft tissue interference screw with additional fixation provided by a button tied over the medial femur; final tension adjustments can then be made by suturing both limbs of the graft together as they enter the femoral tunnel. The entire reconstruction can thus be completed in less than 1 hour. Additional potential advantages of this technique include the minimal use of hardware and use of a limited tunnel in the femur. This aspect could prove advantageous in cases of simultaneous ligament reconstructions because it decreases the risk of tunnel convergence and may help to avoid devastating complications such as avascular necrosis of the femur.²¹

Posterolateral corner injuries are rare but, if left untreated, can cause significant disability because of persistent instability and early degeneration of articular cartilage. Although acute repair is the preferred treatment, these injuries are often missed on initial examination and present late, requiring reconstruction. Biomechanical data have shown the importance of the individual structures of the lateral knee, and our current philosophy is to reconstruct both the LCL and the PFL. The docking technique with allograft tissue provides an efficient and secure method of performing this reconstruction.

REFERENCES

1. Kannus P. Nonoperative treatment of grade II and III sprains of the lateral ligament compartment of the knee. *Am J Sports Med* 1989;17:83-88.
2. Baker CL Jr, Norwood LA, Hughston JC. Acute posterolateral rotatory instability of the knee. *J Bone Joint Surg Am* 1983; 65:614-618.
3. Baker CL Jr, Norwood LA, Hughston JC. Acute combined posterior cruciate and posterolateral instability of the knee. *Am J Sports Med* 1984;12:204-208.
4. Noyes FR, Barber-Westin SD. Surgical restoration to treat chronic deficiency of the posterolateral complex and cruciate ligaments of the knee joint. *Am J Sports Med* 1996;24:415-426.
5. Hughston JC, Jacobson KE. Chronic posterolateral rotatory instability of the knee. *J Bone Joint Surg Am* 1985;67:351-359.
6. Seebacher JR, Inglis AE, Marshall JL, Warren RF. The struc-

- ture of the posterolateral aspect of the knee. *J Bone Joint Surg Am* 1982;64:536-541.
7. Veltri DM, Warren RF. Posterolateral instability of the knee. *Instr Course Lect* 1995;44:441-453.
 8. Wascher DC, Grauer JD, Markoff KL. Biceps tendon tenodesis for posterolateral instability of the knee. An in vitro study. *Am J Sports Med* 1993;21:400-406.
 9. Maynard MJ, Deng X, Wickiewicz TL, Warren RF. The popliteofibular ligament: Rediscovery of a key element in posterolateral stability. *Am J Sports Med* 1996;24:311-316.
 10. Gollehon DL, Torzilli PA, Warren RF. The role of the posterolateral and cruciate ligaments in the stability of the human knee. A biomechanical study. *J Bone Joint Surg Am* 1987;69:233-242.
 11. Veltri DM, Warren RF. Anatomy, biomechanics, and physical findings in posterolateral knee instability. *Clin Sports Med* 1994;13:599-614.
 12. Veltri DM, Deng XH, Torzilli PA, Maynard MJ, Warren RF. The role of the popliteofibular ligament in stability of the human knee. A biomechanical study. *Am J Sports Med* 1996;24:19-27.
 13. Freeman RT, Duri ZA, Dowd GS. Combined chronic posterior cruciate and posterolateral corner ligamentous injuries: A comparison of posterior cruciate ligament reconstruction with and without reconstruction of the posterolateral corner. *Knee* 2002;9:309-312.
 14. Fanelli GC, Larson RV. Practical management of posterolateral instability of the knee. *Arthroscopy* 2002;18:1-8.
 15. O'Brien SJ, Warren RF, Pavlov H, Panariello R, Wickiewicz TL. Reconstruction of the chronically insufficient anterior cruciate ligament with the central third of the patellar ligament. *J Bone Joint Surg Am* 1991;73:278-286.
 16. Skyhar MJ, Warren RF, Ortiz GJ, Schwartz E, Otis JC. The effects of sectioning of the posterior cruciate ligament and the posterolateral complex on the articular contact pressures within the knee. *J Bone Joint Surg Am* 1993;75:694-699.
 17. Covey DC. Injuries of the posterolateral corner of the knee. *J Bone Joint Surg Am* 2001;83:106-118.
 18. Veltri DM, Deng XH, Torzilli PA, Warren RF, Maynard MJ. The role of the cruciate and posterolateral ligaments in stability of the knee. A biomechanical study. *Am J Sports Med* 1995;23:436-443.
 19. Chen FS, Rokito AS, Pitman MI. Acute and chronic posterolateral rotatory instability of the knee. *J Am Acad Orthop Surg* 2000;8:97-110.
 20. Rohrbough JT, Altchek DW, Hyman J, Williams RJ III, Botts JD. Medial collateral ligament reconstruction of the elbow using the docking technique. *Am J Sports Med* 2002;30:541-548.
 21. Athanasian EA, Wickiewicz TL, Warren RF. Osteonecrosis of the femoral condyle after arthroscopic reconstruction of a cruciate ligament: Report of two cases. *J Bone Joint Surg Am* 1995;77:1418-1422.