

# Bony Incorporation of Soft Tissue Anterior Cruciate Ligament Grafts in an Animal Model

## Autograft Versus Allograft With Low-Dose Gamma Irradiation

Sanjeev Bhatia,\* MD, Rebecca Bell,\* BS, Rachel M. Frank,\* MD, Scott A. Rodeo,<sup>†</sup> MD, Bernard R. Bach Jr,\* MD, Brian J. Cole,\* MD, MBA, Susanna Chubinskaya,\* PhD, Vincent M. Wang,\* PhD, and Nikhil N. Verma,\*<sup>‡</sup> MD

*Investigation performed at Rush University Medical Center, Chicago, Illinois*

**Background:** The effect of low-dose gamma irradiation on healing of soft tissue allografts remains largely unknown.

**Hypothesis:** The authors hypothesized that soft tissue allograft healing to bone would be delayed compared with that of autograft tissue and that low-dose (1.2 Mrad) gamma irradiation would not affect the healing response of allograft tissue after anterior cruciate ligament (ACL) reconstruction.

**Study Design:** Controlled laboratory study.

**Methods:** Forty-eight New Zealand White rabbits underwent bilateral ACL reconstructions with semitendinosus tendon graft. Sixteen rabbits were reconstructed with autografts and the remainder with allografts. The 32 allograft rabbits each received 1 irradiated allograft (1.2 Mrad), with the contralateral leg receiving a nonirradiated allograft. Animals were euthanized at 2 weeks or 8 weeks postoperatively. Tensile stiffness, maximum load, and displacement at maximum load were measured. Tibial and femoral segments were sectioned perpendicular to the tunnel axis allowing for histologic and histomorphometric analyses at the tendon-bone interface.

**Results:** There were no significant differences between the maximum load or stiffness values among all groups at 8 weeks. At 2 weeks, autograft exhibited significantly ( $P < .01$ ) lower maximum load than did the nonirradiated grafts. Regarding histology, at both 2- and 8-week time points, autograft tendon displayed more advanced degenerative and remodeling processes in comparison with irradiated allograft and nonirradiated allograft.

**Discussion:** The maximum load and stiffness of a healing tendon allograft in ACL reconstruction appear to be unaltered by low-dose (1.2 Mrad) irradiation. At 8 weeks, there were no biomechanical differences in tendon-bone healing of allografts when compared with autograft controls. Histologic analyses suggested a faster remodeling response in autograft specimens in comparison with allografts at both time points.

**Clinical Relevance:** The findings support the contention that low-dose gamma irradiation is safe for sterilization of ACL soft tissue allografts without compromise of graft properties at early time points.

**Keywords:** soft tissue healing; bony incorporation; tendon-to-bone healing; anterior cruciate ligament (ACL); ACL reconstruction; ACL; gamma irradiation; low dose; hamstring grafts; autograft

<sup>‡</sup>Address correspondence to Nikhil N. Verma, MD, Department of Orthopaedics, Rush University Medical Center, 1611 W. Harrison Street, Suite 201, Chicago, IL 60612 (e-mail: nverma@rushortho.com).

\*Division of Sports Medicine, Department of Orthopaedic Surgery, Rush University Medical Center, Chicago, Illinois.

<sup>†</sup>Department of Sports Medicine, Department of Orthopaedic Surgery, Hospital for Special Surgery, New York, New York.

One or more of the authors has declared the following potential conflict of interest or source of funding: This project was funded by the American Orthopaedic Society for Sports Medicine Young Investigator Grant.

Allograft tendons have emerged as popular alternatives to autograft anterior cruciate ligament (ACL) reconstruction. Tissue that is typically used for ACL allografts includes bone–patellar tendon constructs, as well as soft tissue grafts such as semitendinosus, Achilles, or anterior tibialis tendons. Although bone–patellar tendon–bone (BPTB) allografts have the advantage of high initial fixation strength with early bone-to-bone healing, they have a considerably lower availability in tissue banks compared with soft tissue ACL allografts. In addition, the length of BPTB allografts must match closely with the recipient to avoid graft-tunnel length mismatch. If significant graft-tunnel length mismatch

TABLE 1  
Experimental Groups With Treatments and Time Points for Analysis<sup>a</sup>

Group	No. of Animals	Left Knee Treatment	Right Knee Treatment	Time Point (Postoperative), wk
1	8	ACLR (autograft)	ACLR (autograft)	2
2	8	ACLR (autograft)	ACLR (autograft)	8
3	16	ACLR (1.2 Mrad irradiated allograft)	ACLR (nonirradiated allograft)	2
4	16	ACLR (1.2 Mrad irradiated allograft)	ACLR (nonirradiated allograft)	8

<sup>a</sup>ACLR, anterior cruciate ligament reconstruction.

occurs, adequate fixation of the bone block in the tibial tunnel is difficult or impossible, and other less reliable and more time-consuming methods of fixation must be substituted.<sup>6</sup> Because of these limitations, soft tissue allografts are emerging as a popular choice for ACL reconstruction.

Potential advantages of allograft usage in ACL reconstruction include decreased surgical time, decreased surgical morbidity, and unaltered patellofemoral tracking.<sup>7</sup> However, the use of allograft tissue is not without associated disadvantages. Allografts have decreased osteoinductive and osteoconductive characteristics, as well as increased incorporation times when compared with autograft tissue.<sup>12,19,32</sup> Moreover, although allograft ACL surgery is considered safe, cadaveric tissue can transmit blood-borne disease such as hepatitis, bacterial or fungal infection, and HIV.<sup>11,33</sup> To minimize the risk of transmission, tissue banks perform aggressive donor and graft screening, as well as secondary graft sterilization commonly using gamma irradiation. Initially, human tissue allografts were irradiated with 2.5 to 5 Mrad (25-50 kGy), "high-dose radiation," which compromised graft structural integrity and resulted in high failure rates.<sup>38</sup> More recent secondary sterilization protocols have employed lower irradiation doses, typically from 1 to 1.8 Mrad (10-18 kGy), and are frequently termed "low-dose radiation."<sup>38</sup> These protocols sometimes also incorporate radioprotectant solutions to further protect allograft integrity.<sup>17</sup> Time zero studies conducted on low-dose irradiated allografts suggest that the preimplantation biomechanical properties are not altered when allografts are irradiated at these lower levels.<sup>3</sup>

It is well known that gamma irradiation may compromise the preimplantation structural and mechanical properties of the graft in a dose-dependent manner.<sup>4,9,10,13,18,26</sup> However, in vivo effects of irradiation on soft tissue–bone healing and the ligamentization process are poorly understood. To our knowledge, there are no published reports on soft tissue ACL allograft healing (ie, tendon-to-bone healing) after irradiation treatment. The purpose of this study was to biomechanically and histologically compare soft tissue healing in a bone tunnel over a 2- and 8-week time period using 3 types of ACL hamstring grafts: nonirradiated allografts, low-level (1.2 Mrad) gamma-irradiated allografts, and autograft controls. We hypothesized that soft tissue allograft tendon-to-bone healing would be delayed compared with that of autograft tissue and that low-dose (1.2 Mrad) gamma irradiation would not affect the healing response of allograft tissue after ACL reconstruction.

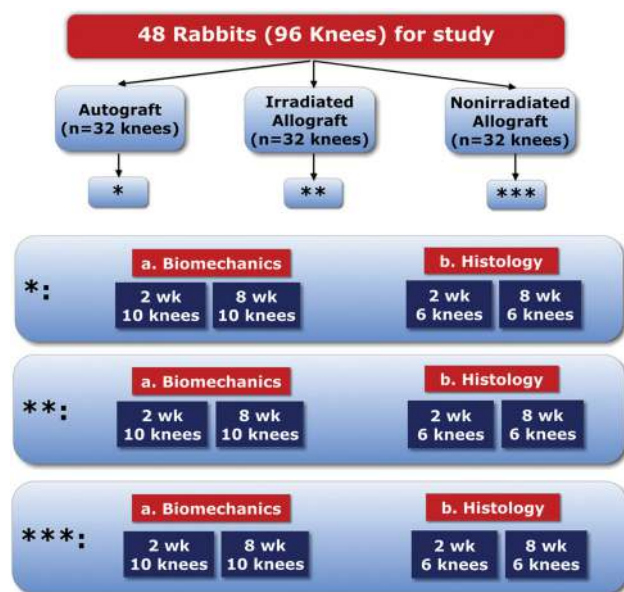
## METHODS

### In Vivo Animal Model

This study design was based on an established model of ACL reconstruction performed in skeletally mature, male New Zealand White rabbits.<sup>15,29</sup> Animals were procured from a licensed rabbit farm and were not inbred to strengthen the allograft model. The protocols described below were reviewed and approved by our institutional animal care and use committee.

### Experimental Design

A total of 58 skeletally mature, male New Zealand White rabbits with a mean weight of 3.5 kg at the time of surgery were included in the study. Forty-eight rabbits underwent bilateral ACL reconstruction with semitendinosus tendon grafts. The rabbits were divided into 4 study groups (Table 1). Animals in groups 1 (5 rabbits for biomechanics, 3 rabbits for histology; 2-week time point) and 2 (5 rabbits for biomechanics, 3 rabbits for histology; 8-week time point) received bilateral ACL autograft reconstructions; grafts were harvested and used for ACL reconstruction during the same procedure. Animals in groups 3 (10 rabbits for biomechanics, 6 rabbits for histology; 2-week time point) and 4 (10 rabbits for biomechanics, 6 rabbits for histology; 8-week time point) received bilateral ACL allograft reconstructions with an irradiated allograft placed in the left knee and a nonirradiated allograft placed in the right knee to serve as a control. Ten rabbits (20 tendons) were used exclusively for semitendinosus tendon allograft harvest. To minimize the number of animals, tendon allografts were also procured from rabbits designated for allograft ACL reconstruction (groups 3 and 4). Thus, all animals included in the experimental groups (1, 2, 3, and 4) underwent a bilateral semitendinosus tendon harvest and autograft or allograft ACL reconstruction. Each harvested allograft was maintained in our freezer until the time of ACL reconstruction. If the specimen was in an irradiation group, the allograft was maintained in our freezer up through the morning of irradiation, and throughout the irradiation process the allograft was kept on dry ice to prevent any additional freeze-thaw cycles. Each allograft was then thawed intraoperatively immediately before implantation. A summary of the study design is depicted in Figure 1.



**Figure 1.** Summary of experimental design. Forty-eight skeletally mature, male New Zealand White rabbits (96 knees) underwent bilateral anterior cruciate ligament reconstruction with semitendinosus tendon grafts. Sixteen rabbits (32 knees) were in the autograft group, whereas 32 rabbits (64 knees) were in the allograft group.

### Surgical Procedure

After induction of anesthesia and administration of cefazolin, the rabbit's bilateral lower extremities were shaved, prepared with sequential povidone/iodine (Betadine) scrubs, and draped. A 4-cm anteromedial skin incision was made over the knee, and the semitendinosus tendon was harvested from its musculotendinous junction to its insertion on the posterior proximal tibial shaft. In rabbits assigned to groups 1 and 2 (autograft reconstruction), a 3-0 Ethibond suture was used to place a Krakow stitch on each end of the graft (Figure 2). In rabbits assigned to groups 3 and 4 (allograft reconstruction), after harvest, the grafts were immediately wrapped in saline-soaked sterile gauze and placed in sterile specimen cups and frozen at  $-20^{\circ}\text{C}$ . Half of these grafts received secondary gamma sterilization to 1.2 Mrad with Cobalt 60 irradiation at Steris Isomedix Inc (Libertyville, Illinois); grafts were irradiated at  $-20^{\circ}\text{C}$ , and specialized dosimeters were used to confirm delivery of the required dose of gamma radiation. The technique used was identical to that used for human tissue prepared for clinical use at our medical center. After treatment, these grafts were maintained in a  $-20^{\circ}\text{C}$  freezer until needed for subsequent surgeries.

Using the same skin incision, a 2-cm medial parapatellar arthrotomy was made. The patella was dislocated laterally, and the native ACL was excised. A 2.0-mm drill was used to create a tibial and femoral tunnel through the respective ACL footprints. The semitendinosus graft was

passed through the tunnels with the use of a 3-0 Ethibond shuttle suture. Grafts were manually tensioned, and each suture end was secured to a collateral ligament origin (femur) followed by tensioning of the graft with the knee in  $90^{\circ}$  of flexion and suturing at the medial collateral insertion (tibia). The knee joint was subjected to 10 cycles of flexion-extension motion to verify stability of the reconstructed joint. The joint capsule and skin were closed in standard fashion using 4-0 Vicryl suture. The identical procedure was then performed in the opposite knee. Each rabbit in groups 1 and 2 received bilateral autograft reconstruction; each rabbit in groups 4 and 5 received an irradiated allograft in the left knee and a nonirradiated allograft in the right knee.

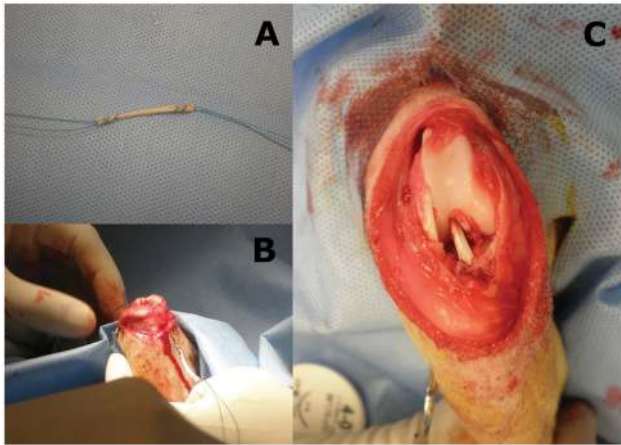
Wounds were not dressed or bandaged, and the legs were not immobilized postoperatively. Rabbits were housed in individual cages with no restrictions on their movement. At the designated time points (2 or 8 weeks postoperatively), all rabbits were sacrificed.

### Gross (Macroscopic) Tissue Assessment

After animal sacrifice, each hindlimb was disarticulated at the hip joint and was separated from the ankle joint. The knee joint was carefully dissected, and the graft's insertion sites and midsubstance were assessed for hypertrophy, vascularity, scar tissue formation, and other signs of inflammatory reactions. Gross changes in the joint and surrounding soft tissues as well as synovial fluid were noted. Healing ACL grafts designated for biomechanical analyses were covered with saline-soaked gauze, placed in hermetically sealed bags, and frozen at  $-20^{\circ}\text{C}$  until the day of testing. Specimens designated for histologic assessment were placed in paraformaldehyde immediately after gross examination.

### Biomechanical Evaluation

On the day of the testing, specimens were thawed for 2 hours at room temperature. Throughout preparation and testing, the tissues were kept moist with saline. All surrounding soft connective tissues were dissected, leaving only the ACL tendon graft secured to the femur (proximally) and tibia (distally). With use of custom-designed grips, each specimen was mounted on an electromechanical materials testing system (MTS Insight 5, Eden Prairie, Minnesota). Each specimen was positioned at an approximate flexion angle of  $30^{\circ}$  so that the longitudinal axis of the ACL tendon graft was parallel to that of the test actuator. The upper grip was connected to an in-line 250-N load cell affixed to the test actuator. Each tendon graft was preloaded to 1 N and then preconditioned between 0 and 0.5 mm (actuator displacement) at a rate of 0.1 mm/s for 10 cycles. After preconditioning, a load-to-failure test was conducted using a displacement rate of 0.1 mm/s. Using the load-displacement curve generated from the failure test of each specimen, the following structural properties were computed: (1) maximum load, (2) linear stiffness



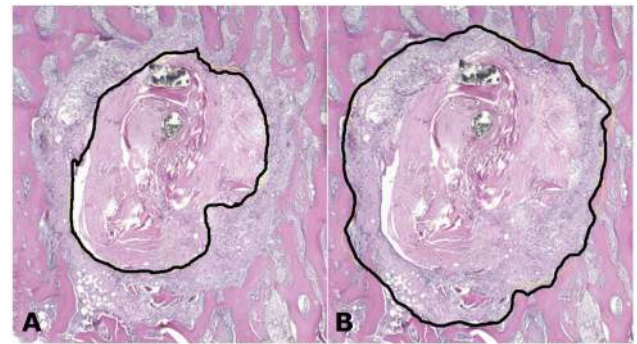
**Figure 2.** Surgical technique for anterior cruciate ligament (ACL) reconstruction. (A) Semitendinosus tendon graft is prepared with Krakow stitch technique using 3-0 Ethibond suture. (B) Tendon graft is passed through tunnels with use of a 4-0 Ethibond stay suture. (C) Final ACL reconstruction. Tendon graft is secured to collateral ligament origins with 4-0 Ethibond suture.

(maximum slope of force vs crosshead displacement curve encompassing a minimum of 40% of the total number of data points from test initiation to maximum load), and (3) crosshead displacement at maximum load. The location of construct failure (eg, tunnel or graft midsubstance) was noted.

### Histologic Evaluation

After gross assessment as specified above, the distal femur and proximal tibia were resected while preserving the entire length of the respective bone tunnels. Samples were fixed in paraformaldehyde and then decalcified in a solution of formic acid/sodium citrate. Each sample was divided into 2 portions prior to paraffin embedding in separate histologic blocks: (1) proximal tibia and (2) distal femur. To facilitate determination of the amount of tissue formation between the tendon graft and bone tunnel, the tibial and femoral segments were sectioned perpendicular to the tunnel axis (at the midportion of the tunnel length). Tendon-bone tissue interface tissue sections were stained with hematoxylin and eosin and Masson trichrome. Articular cartilage and synovial tissues were not examined.

Comparisons were made between 2 time points of the same treatment and at each time point among all 3 treatments in a manner consistent with the literature.<sup>16,28,29</sup> As noted by Greis et al,<sup>16</sup> remodeling was deemed to occur if areas of woven bone were present surrounding tendon grafts in bone tunnels. Tendon-to-bone healing was evaluated based on the density and organization of collagen fibrils connecting the tendon graft to bone. Low-magnification histologic images provided views of the entire cross-section, whereas higher resolution images facilitated



**Figure 3.** Histomorphometric evaluation. Following the methodology described by Rodeo et al,<sup>28,29</sup> digital pictures were captured from cross-sectional (perpendicular) histologic sections obtained from the midportion of femoral and tibial tunnels. For each of the histologic sections per specimen, the tunnel size and the graft size were measured using Image J software. The amount of new growth within the bone tunnels was determined by subtracting the area of the tendon graft (A) from the area of the bone tunnel (B). The percentage of new growth was determined by normalizing the amount of new growth to the size of the tunnel.

investigation of interfaces between the tendon graft and bone.

### Histomorphometry

Following the methodology described by Rodeo et al,<sup>28,29</sup> digital pictures were captured from cross-sectional (transverse to the long axis of the bone) histologic sections obtained from the midportion of femoral and tibial tunnels. For each of the legs, the tunnel size and the graft size were measured for both the femur and the tibia by 2 blinded observers. As no significant differences were detected between the latter 2 sets of measurements, histomorphometric results reported herein represent the average of the 2 data sets (Figure 3). All measurements were performed using Image J software (National Institutes of Health, Bethesda, Maryland). The amount of new growth within the bone tunnels was determined by subtracting the area of the tendon graft from the area of the bone tunnel. The percentage of new growth was determined by normalizing the amount of new growth to the size of the tunnel.

### Statistical Analysis

Statistical comparisons of biomechanical and histomorphometric results between treatment groups at each time point were performed using a 1-way analysis of variance followed by post hoc pairwise comparisons with the Tukey test. The time points were compared within treatment using a 2-tailed, unpaired Student *t* test. Statistical analyses were performed using GraphPad Prism 5.0 (GraphPad Software Inc, La Jolla, California), and statistical significance was assumed for  $P < .05$ .

TABLE 2  
Summary of Biomechanical Data Among Groups

	Maximum Load, N	Displacement at Maximum Load, mm	Stiffness, N/mm
2-week autograft	18 ± 8 <sup>a</sup>	4.9 ± 2.9	9.0 ± 5.2
2-week nonirradiated	37 ± 11 <sup>a</sup>	5.1 ± 2.6	14.6 ± 6.3
2-week irradiated	28 ± 10	7.0 ± 4.8	12.6 ± 5.4
8-week autograft	28 ± 18	2.3 ± 0.7	17.7 ± 15.2
8-week nonirradiated	31 ± 16	3.3 ± 2.2	14.3 ± 8.7
8-week irradiated	29 ± 20	3.1 ± 1.5	14.9 ± 7.9

<sup>a</sup>Indicates  $P = .003$  for comparisons of the indicated groups. All other groups had  $P > .05$ .

## RESULTS

### Gross Observations

At the 2-week time point, irrespective of graft treatment, knee specimens were slightly swollen with trace amounts of synovial fluid detected. At 8 weeks, regardless of graft treatment, there was less swelling observed when compared to the 2-week time point. In all the specimens, the grafts were intact. Because of complications after surgery, the 8-week nonirradiated group only had 5 tendons available for biomechanical testing. The remaining biomechanical test groups all had at least 7 specimens. Post hoc power analysis revealed that these numbers were adequate: because of the small effect size computed (0.06 for maximum load in the 8-week group), a sample size of more than 1000 would be required to achieve a power of 80% for this effect size. In other words, even if data from 7 specimens were available for all groups at the 8-week time point, a statistical difference would most likely not have been achieved for biomechanical results.

### Biomechanics

A summary of biomechanical data is provided in Table 2. For the 2-week groups, the autograft exhibited significantly ( $P < .01$ ) lower maximum load of  $18 \pm 8$  N compared with the nonirradiated grafts ( $37 \pm 11$  N). There was no statistical difference between the autograft group and the irradiated allograft group ( $28 \pm 10$  N) or between the irradiated allograft group and the nonirradiated allograft group. The displacement at maximum load and the stiffness showed no significant differences among treatment groups. In the autograft group, 8 specimens failed via pullout from the femoral tunnel, 1 specimen failed via pullout from the tibial tunnel, and 1 specimen failed at the graft midsubstance (intra-articular portion). For the nonirradiated allograft group, 3 specimens failed at the femoral tunnel, 1 specimen failed at the tibial tunnel, and 3 specimens failed midsubstance. For the irradiated allograft group, 5 specimens failed at the femoral tunnel, 2 specimens failed at the tibial tunnel, and no specimens failed midsubstance.

The 8-week data demonstrated no significant differences in maximum load, displacement at maximum load, or stiffness among any of the 3 ACL reconstruction specimen types (autograft, nonirradiated allograft, irradiated allograft). In the autograft group, all specimens failed at the

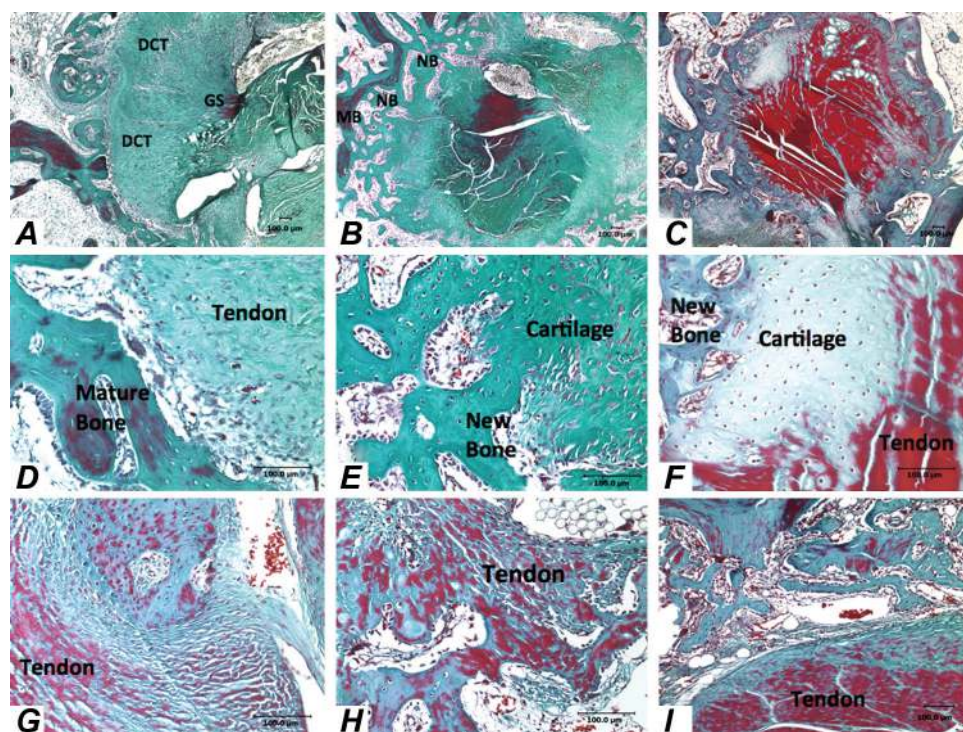
midsubstance. For the nonirradiated allograft group, 1 specimen failed at the femoral tunnel fixation, 1 specimen failed at the tibial tunnel fixation, and the remainder, 3, failed within the midsubstance. For the irradiated allograft group, all 8 specimens failed in the midsubstance.

### Histology

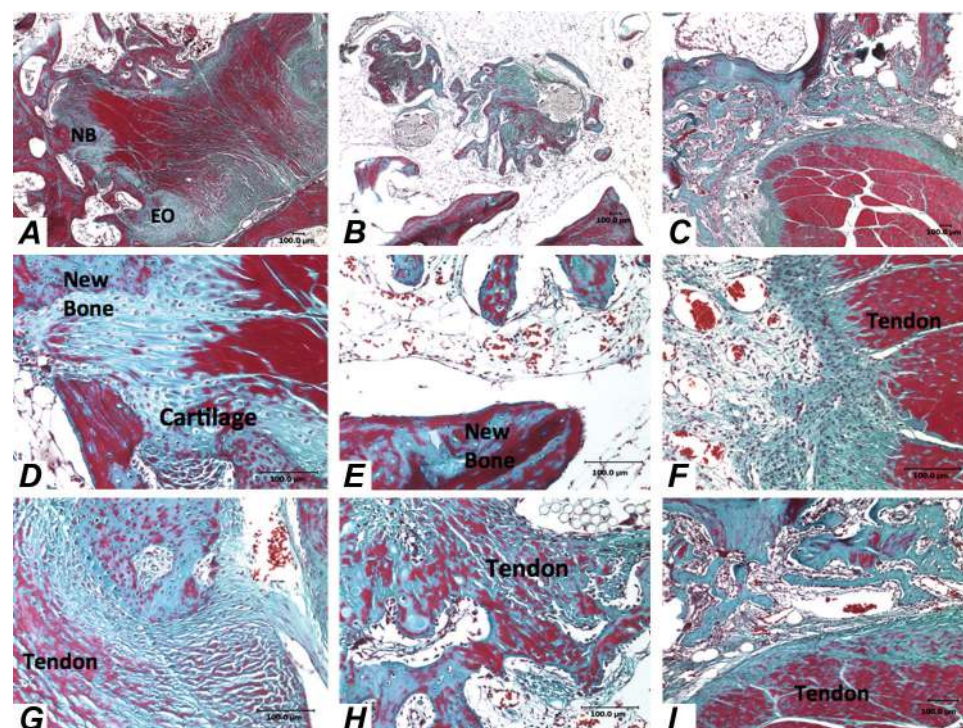
At 2 weeks postoperatively for the autograft tendon samples (Figure 4A), both degenerative and remodeling processes could be seen. Thus, the tendon apparently undergoes degenerative changes characterized by almost complete lack of red staining of Masson trichrome, suggesting a loss of ground substance; only traces of staining could be seen in the central portion of the tendon. On the periphery of the tendon (Figures 4 D and G), regular matrix was replaced with dense connective tissue. Furthermore, remnants of bone surrounded by phagocytes could also be visualized. Few osteoclasts were identified at the healing tendon-bone junction. The walls of the canal displayed intensive bone remodeling with osteoblasts, newly formed blood vessels, and fibroblasts. By 8 weeks, samples receiving autograft showed signs of active remodeling and regeneration characterized by intense Masson trichrome red staining (Figure 5A). Dense connective tissue matrix was deposited at the healing tendon-bone interface (Figures 5 D and G). Areas of endochondral ossification and newly formed cartilage were also evident, especially at the border with bone. There was also evidence of both mature lamellar bone and newly formed bone.

Very different processes were observed with nonirradiated allograft samples at both time points. At 2 weeks (Figure 4B), nonirradiated tendon did not show severe signs of degeneration as was seen in the autograft sample, yet the tendon edema was present causing the development of tendon bundles with infiltrates of cells (Figure 4H). Tendon was surrounded by loose connective tissue with blood vessels and cell infiltrates. Centers of ossification and intensive bone remodeling were present as well as the segments of bone surrounded by osteoclasts (Figure 4E). By 8 weeks (Figures 5 B, E, and H), nonirradiated tendon was totally degenerated and was replaced with newly formed cartilage, bone, bone marrow cavities, and blood vessels.

Irradiated allograft tendon at the 2-week time point did not display signs of remodeling and degeneration as seen



**Figure 4.** Masson trichrome staining of tendon autograft at 2 weeks after surgery. (A) Low magnification ( $\times 4$ ) of the autograft and surrounding tissues. (B) Low magnification ( $\times 4$ ) of the nonirradiated allograft and surrounding tissues. (C) Low magnification ( $\times 4$ ) of the irradiated allograft and surrounding tissues. (D, G) High magnification ( $\times 20$ ) of the autograft and surrounding tissues. (E, H) High magnification ( $\times 20$ ) of the nonirradiated allograft and surrounding tissues. (F, I) High magnification ( $\times 20$ ) of the irradiated allograft and surrounding tissues.



**Figure 5.** Masson trichrome staining of tendon autograft at 8 weeks after surgery. (A) Low magnification ( $\times 4$ ) of the autograft and surrounding tissues. (B) Low magnification ( $\times 4$ ) of the nonirradiated allograft and surrounding tissues. (C) Low magnification ( $\times 4$ ) of the irradiated allograft and surrounding tissues. (D, G) High magnification ( $\times 20$ ) of the autograft and surrounding tissues. (E, H) High magnification ( $\times 20$ ) of the nonirradiated allograft and surrounding tissues. (F, I) High magnification ( $\times 20$ ) of the irradiated allograft and surrounding tissues.

in the autograft tendon (Figure 4C). Tendon ground substance appeared normal (Figure 4I). The walls of the canal displayed areas of endochondral ossification with new bone formation that extended into mature bone (Figure 4F). There was also evidence of chondrogenesis, formation of new bone marrow cavities, and formation of blood vessels.

Fibers of sutures were infiltrated by single cells. By 8 weeks, irradiated allograft tendon displayed noticeable osteogenesis characterized by newly formed bone organized around the allograft with areas of bone ingrowth into the allograft (Figure 5C). Contrary to the autograft tendon at the same time point, newly formed bone of the

TABLE 3  
Summary of Histomorphometric Data<sup>a</sup>

	Total New Growth, %
2-week autograft	44 ± 12
2-week nonirradiated	37 ± 10
2-week irradiated	43 ± 18
8-week autograft	43 ± 18
8-week nonirradiated	44 ± 21
8-week irradiated	42 ± 14

<sup>a</sup>No statistical differences were noted among groups at either time point, nor within each group between time points.

irradiated allograft showed a considerable amount of calcification as indicated by red staining (Figures 5 F and I).

### Histomorphometry

A summary of histomorphometric data is provided in Table 3. As no significant differences were detected between histologic sections obtained from the midportion of femoral and tibial tunnels, histomorphometric results reported herein represent the average of the 2 data sets. At 2 weeks, there was no significant difference between the grafts with the autograft at 44% ± 12% new growth, irradiated allograft at 43% ± 18% new growth, and the nonirradiated graft at 37% ± 10% new growth. Histomorphometric analysis of the 8-week specimens also demonstrated no statistical difference between any of the grafts. The percentage new tissue growth for autografts, irradiated allografts, and nonirradiated allografts were, respectively, 43% ± 18%, 42% ± 14%, and 44% ± 21%.

### DISCUSSION

Soft tissue allografts have become a popular alternative in ACL reconstruction procedures as they circumvent the problem of graft-tunnel mismatch, often experienced when using BPTB allografts, and allow for decreased surgical time, decreased surgical morbidity, and unaltered patellofemoral tracking.<sup>6</sup> Low-dose gamma irradiation has emerged as an effective means for sterilization of soft tissue allografts—dosages as low as 1.0 to 1.5 Mrad can inactivate most microorganisms—but questions surrounding its effect on healing remain.<sup>8,34</sup>

The principal findings of this study demonstrated no significant difference in biomechanical outcomes at 8 weeks among autograft, allograft, and low-dose irradiated semitendinous allograft tendon in a rabbit model of ACL reconstruction. Differences were seen between groups at 2 weeks postoperatively; at this early time point, we noted lower ultimate load to failure in the autograft group in comparison with the nonirradiated allograft group. Regarding histologic findings, several differences were noted between treatment groups, the most striking being that remodeling surrounding autograft tendon ACL constructs appeared faster and more prominent than that

surrounding irradiated tendon ACL allograft constructs. At 2 weeks, autografts had almost complete loss of red staining, tendon degeneration, and intensive remodeling along the walls of the tendon canal. In contrast, irradiated and nonirradiated allografts displayed no tendon degeneration. Irradiated specimens demonstrated chondrogenesis and osteogenesis along the bone tunnel walls, but nonirradiated specimens had intensive bone remodeling similar to that of their autograft counterparts. By 8 weeks, autograft tendon tissue appeared relatively intact, with minimal separation into large bundle and remodeling at desired locations. Irradiated samples, in contrast, were beginning to experience severe remodeling and calcification. Thus, it seems that the irradiated allograft tendon group undergoes the remodeling process slower with a degenerative stage. Although qualitative histologic examinations revealed variations in remodeling and tendon degeneration among groups, quantitative histomorphometric analysis did not demonstrate significant differences between any of the graft types at either postoperative time point.

The findings of faster and more prominent histologic remodeling in autograft tissue and decreased biomechanical properties at 2 weeks in autograft ACL constructs are supported by prior literature on graft incorporation. Jackson et al<sup>19</sup> used a goat patellar tendon ACL reconstruction model to demonstrate that allograft incorporation is much slower and less robust at 6 months in comparison with that of autograft controls. The authors concluded that allograft ACL constructs should be protected for a longer duration than are their autograft tissue counterparts.<sup>19</sup> By the same token, the decreased biomechanical properties of the 2-week autograft may be explained by earlier degeneration, as compared with allograft tissue. As noted by Amiel et al,<sup>1,2</sup> tendon grafts used for ACL reconstruction first undergo a process of necrosis and degeneration with a resultant decline in biomechanical properties followed by revascularization, cellular repopulation, and remodeling. Because the autograft group experienced degenerative changes earlier on, they may have been more predisposed to graft pullout at 2 weeks after operation.<sup>5</sup> A more secure method of fixation for ACL grafts is unlikely to have had a major effect on overall healing of grafts within bone tunnels, particularly because the majority of the 8-week grafts failed at the intrasubstance portion rather than the osseous-tendinous junction during testing; in addition, in all specimens, grafts were intact at time of dissection. The method of fixation, however, may affect bone healing based on the device used. For example, interference screw fixation may have an effect on bone integration based on compression of the graft against the bone and by limitation of surface area of bone contacting the graft.

In one of the few studies examining effects of low-dose gamma irradiation in an ex vivo ACL reconstruction model, McGilvray et al<sup>22</sup> noted no detrimental effects of low-dose (1.5 Mrad) irradiation when compared with a nonirradiated control. High-dose irradiation (2.5 Mrad) did compromise bulk tendon load at failure and ultimate strength by 26.9% and 28.9%, respectively ( $P < .05$ ). To our knowledge, no studies have examined the effects of

1.2 Mrad of irradiation, the same dose used in this study and the dose currently used by our allograft tissue bank supplier (Allosource, Centennial, Colorado).

To date, several authors have investigated allograft healing after irradiation treatment.<sup>14,21,31</sup> The majority of these studies, however, have examined allograft healing in situations with bone-to-bone interfaces (eg, BPTB ACL allograft reconstruction)<sup>14,31</sup> or in models that are not subject to the strains, stresses, or the intrasynovial environment of an ACL.<sup>21</sup> Mae et al,<sup>21</sup> using a rat patellar tendon model (not ACL model), reported a significant difference in preimplantation properties between nonirradiated patellar tendon grafts and those receiving 2.5 Mrad treatment. The authors noted no differences at healing time points of 12 and 24 weeks after implantation. Schwartz et al,<sup>31</sup> in a study investigating effects of gamma irradiation in an in vivo goat ACL reconstruction healing model, found significant differences in the preimplantation anterior load ratio of 4 Mrad irradiated versus nonirradiated patellar tendon grafts. At 6 months postoperatively, although they found no difference in modulus, maximum stress, or biochemical composition, the authors reported a significant decrease in stiffness and maximum force in the irradiated group. Goertzen et al<sup>14</sup> performed ACL allograft reconstruction in foxhounds using both a 2.5-Mrad gamma-irradiated BPTB graft and a nonirradiated control. At 12 months after implantation, the authors found no significant difference in maximum load to failure. Microangiography studies did, however, show a slight hypervascularity in the irradiated group. To our knowledge, however, no studies have compared biomechanical properties or tendon-to-bone healing using a soft tissue graft.

Several authors have examined tendon graft healing in ACL reconstruction performed with bone-to-bone fixation (ie, BPTB) compared with ACL reconstruction using soft tissue fixation (ie, hamstring). Both bone healing and soft tissue healing undergo a biological healing response involving the formation of fibrovascular tissue and eventual bony incorporation at the healing interface, beginning around day 20 after implantation and taking up to 12 months to complete.<sup>29,30</sup> The difference between the 2 types of graft incorporation is rate and strength of healing, which has substantial clinical significance with regard to rehabilitation and return to activity. Several soft tissue models have noted sufficient tendon-to-bone healing in using the semitendinosus tendon in an animal model in as little as 3 weeks, as well as up to 24 weeks.<sup>15,18</sup> In a study by Park et al,<sup>23</sup> bone-to-bone healing was directly compared with tendon-to-bone healing in a rabbit model. The authors reported faster and stronger incorporation of bone-to-bone graft early on in the study period (up to 8 weeks); however, they noted that by 12 weeks, there were no significant biomechanical differences between the groups.<sup>23</sup> Clinically, Pinczewski et al<sup>24</sup> recently performed a 10-year prospective study comparing BPTB ACL reconstruction to quadruple hamstring ACL reconstruction. The authors noted similar subjective, objective, and functional outcomes in both groups.

Very few clinical studies have examined differences in outcomes between patients receiving irradiated ACL

allografts and those receiving nonirradiated ones.<sup>25,27,35</sup> Sun et al<sup>35</sup> used a prospective randomized study design to examine clinical outcomes of arthroscopic ACL reconstruction with irradiated BPTB allograft compared with nonirradiated allograft and autograft. At a mean of 31 months after surgical follow-up, the authors found that the failure rate among patients receiving an irradiated BPTB allograft (2.5 Mrad) was significantly higher (34.4%) than the rate among patients receiving an autograft (6.1%) or a nonirradiated allograft (8.8%). These unsatisfactory clinical results led the senior surgeon to discontinue the use of irradiated BPTB allograft in ACL surgery.<sup>35</sup> In 2 separate studies, the same authors also investigated clinical outcomes in patients undergoing ACL reconstruction with hamstring autograft, nonirradiated hamstring allograft, and irradiated (2.5 Mrad) hamstring allograft. In both studies, the cohort undergoing ACL reconstruction with irradiated allografts demonstrated significantly decreased anterior and rotational stability in the operated knee, but no clear difference in functional testing could be found.<sup>36,37</sup> Similarly, Rappe et al<sup>25</sup> performed a retrospective cohort study of patients undergoing ACL reconstruction with nonirradiated and irradiated (2.0-2.5 Mrad) Achilles allografts. At a minimum of 6-month postoperative follow-up, the authors noted a 2.4% catastrophic failure rate among patients receiving nonirradiated grafts versus a 33% failure rate among patients receiving irradiated grafts. These results also led the authors to discontinue the use of irradiated allografts in ACL reconstruction. It should be noted, however, that the dose of irradiation employed in the aforementioned studies was higher, almost double, than current low-dose gamma irradiation sterilization protocols and the 1.2 Mrad used in this study. Furthermore, as discussed previously, biomechanical testing has shown compromised structural properties in tendon grafts exposed to irradiation doses above 2.0 Mrad.<sup>38</sup>

A second study also involving 102 patients undergoing ACL reconstruction with either autograft BPTB or allograft BPTB irradiated with 2.5 Mrad found no difference in clinical outcome.<sup>27</sup> Thirty-nine patients (mean age, 44 ± 8.4 years) received allografts, whereas 63 patients (mean age, 25.3 ± 9.3 years) received autografts. The authors followed patients for a mean 4.2 years and found no difference in subjective scores or age-adjusted KT-1000 arthrometer measures. Regarding return to sport, 66.7% of the allograft group and 77.8% of the autograft group returned to the same or more strenuous level of sports ( $P = .25$ ). They concluded that irradiation can be used to sterilize BPTB allograft without adversely affecting clinical outcome.

The major strength of the current study is the use of a previously established in vivo model with ability to evaluate both biomechanical and histologic properties of soft tissue autograft and allograft up to 8 weeks after implantation. There are several limitations to the study, however. First, this is an in vivo animal model, and rabbit healing after ACL reconstruction, although validated in numerous previous studies, may be different than that of humans. Rabbits are not able to undergo immobilization

or limb protection after surgery, which could have affected graft healing. In addition, graft fixation was different than that of humans. Second, allograft rabbits all received an irradiated graft in the left knee and a nonirradiated graft in the right knee. Although rabbits are quadrupeds, and issues such as paw dominance are less likely to be clinically significant, subtle differences could have existed. Third, we did not histologically evaluate the intra-articular portion of the graft and therefore are unable to comment on the neoligamentization process that likely occurs during healing of the tendon graft in vivo. In this initial study, our principal histologic assessment was incorporation of tendon grafts in the bone tunnels. We plan to examine the intra-articular portion of the grafts in future studies. Finally, our study only examined outcomes up to 8 weeks postoperatively, and therefore we cannot comment on possible differences that may be present at longer follow-up time points. However, a detailed analysis of published biomechanical data from rabbit ACL reconstruction studies in which healing time points up to 1 year were analyzed revealed that the majority of healing occurs by 8 weeks after surgery. For instance, Labs et al<sup>20</sup> reported that at 8 weeks of healing, the magnitudes of maximum load and tensile stiffness were 84% and 78%, respectively, of grafts examined at 32 weeks. Thus, for comparative purposes, we believe that an 8-week time point provided a reasonable assessment of long-term healing potential of rabbit ACL grafts.

## CONCLUSION

The principal findings of this study demonstrated no observed biomechanical or histomorphometric differences in healing between autograft, allograft, and low-dose irradiated allograft at 8 weeks after implantation. Histologically, it appears that low-dose irradiated allograft tendons undergo remodeling later than do autograft and nonirradiated allograft tendons without a substantial degenerative stage that is seen in autograft soft tissue tendon grafts. Such findings support the contention that low-dose gamma irradiation is safe for sterilization of ACL soft tissue allografts without compromise of graft properties at early time points. Although the current study did not find detrimental effects of gamma irradiation at the tested level (1.2 Mrad), higher doses may have negative effects on healing.<sup>3,7,8,11,21,30</sup> Additional studies are needed to fully delineate these effects.

## ACKNOWLEDGMENT

We acknowledge Dr Sue Leurgans for her consultation in regard to the statistics.

## REFERENCES

1. Amiel D, Kleiner JB, Akeson WH. The natural history of the anterior cruciate ligament autograft of patellar tendon origin. *Am J Sports Med.* 1986;14(6):449-462.
2. Amiel D, Kleiner JB, Roux RD, Harwood FL, Akeson WH. The phenomenon of "ligamentization": anterior cruciate ligament reconstruction with autogenous patellar tendon. *J Orthop Res.* 1986;4(2):162-172.
3. Balsly CR, Cotter AT, Williams LA, Gaskins BD, Moore MA, Wolfinger L Jr. Effect of low dose and moderate dose gamma irradiation on the mechanical properties of bone and soft tissue allografts. *Cell Tissue Bank.* 2008;9(4):289-298.
4. Belkoff SM, Haut RC. Microstructurally based model analysis of gamma-irradiated tendon allografts. *J Orthop Res.* 1992;10(3):461-464.
5. Bosch U, Kasperczyk WJ. Healing of the patellar tendon autograft after posterior cruciate ligament reconstruction: a process of ligamentization? An experimental study in a sheep model. *Am J Sports Med.* 1992;20(5):558-566.
6. Brown JA, Brophy RH, Franco J, et al. Avoiding allograft length mismatch during anterior cruciate ligament reconstruction: patient height as an indicator of appropriate graft length. *Am J Sports Med.* 2007;35(6):986-989.
7. Buss DD, Warren RF, Wickiewicz TL, Galinat BJ, Panariello R. Arthroscopically assisted reconstruction of the anterior cruciate ligament with use of autogenous patellar-ligament grafts: results after twenty-four to forty-two months. *J Bone Joint Surg Am.* 1993;75(9):1346-1355.
8. Christensen EA, Kristensen AR, Sehestad K. Radiation sterilization. In: Russel AD, Hug WB, Ayliffe GA, eds. *Principles and Practices of Disinfection, Preservation, and Sterilization.* London, England: Blackwell; 1982:513-533.
9. Donald PJ, Deckard-Janatpour K, Sharkey N, Lagunas-Solar M. The effects of irradiation dose on the stiffness of cartilage grafts. *Ann Plast Surg.* 1996;36(3):297-303.
10. Fideler BM, Vangsness CT Jr, Lu B, Orlando C, Moore T. Gamma irradiation: effects on biomechanical properties of human bone-patellar tendon-bone allografts. *Am J Sports Med.* 1995;23(5):643-646.
11. Fideler BM, Vangsness CT Jr, Moore T, Li Z, Rasheed S. Effects of gamma irradiation on the human immunodeficiency virus: a study in frozen human bone-patellar ligament-bone grafts obtained from infected cadavera. *J Bone Joint Surg Am.* 1994;76(7):1032-1035.
12. Gazdag AR, Lane JM, Glaser D, Forster RA. Alternatives to autogenous bone graft: efficacy and indications. *J Am Acad Orthop Surg.* 1995;3(1):1-8.
13. Gibbons MJ, Butler DL, Grood ES, Bylski-Austrow DI, Levy MS, Noyes FR. Effects of gamma irradiation on the initial mechanical and material properties of goat bone-patellar tendon-bone allografts. *J Orthop Res.* 1991;9(2):209-218.
14. Goertzen MJ, Clahsen H, Schultiz KP. Anterior cruciate ligament reconstruction using cryopreserved irradiated bone-ACL-bone-allograft transplants. *Knee Surg Sports Traumatol Arthrosc.* 1994;2(3):150-157.
15. Grana WA, Egle DM, Mahnen R, Goodhart CW. An analysis of autograft fixation after anterior cruciate ligament reconstruction in a rabbit model. *Am J Sports Med.* 1994;22(3):344-351.
16. Greis PE, Burks RT, Bachus K, Luker MG. The influence of tendon length and fit on the strength of a tendon-bone tunnel complex: a biomechanical and histologic study in the dog. *Am J Sports Med.* 2001;29(4):493-497.
17. Grieb TA, Forng RY, Bogdansky S, et al. High-dose gamma irradiation for soft tissue allografts: high margin of safety with biomechanical integrity. *J Orthop Res.* 2006;24(5):1011-1018.
18. Haut RC, Powlison AC. The effects of test environment and cyclic stretching on the failure properties of human patellar tendons. *J Orthop Res.* 1990;8(4):532-540.
19. Jackson DW, Grood ES, Goldstein JD, et al. A comparison of patellar tendon autograft and allograft used for anterior cruciate ligament reconstruction in the goat model. *Am J Sports Med.* 1993;21(2):176-185.
20. Labs K, Perka C, Schneider F. The biological and biomechanical effect of different graft tensioning in anterior cruciate ligament reconstruction: an experimental study. *Arch Orthop Trauma Surg.* 2002;122(4):193-199.
21. Mae T, Shino K, Maeda A, Toritsuka Y, Horibe S, Ochi T. Effect of gamma irradiation on remodeling process of tendon allograft. *Clin Orthop Relat Res.* 2003;414:305-314.

22. McGilvray KC, Santoni BG, Turner AS, Bogdanský S, Wheeler DL, Puttlitz CM. Effects of (60)Co gamma radiation dose on initial structural biomechanical properties of ovine bone-patellar tendon-bone allografts. *Cell Tissue Bank*. 2011;12(2):89-98.
23. Park MJ, Lee MC, Seong SC. A comparative study of the healing of tendon autograft and tendon-bone autograft using patellar tendon in rabbits. *Int Orthop*. 2001;25(1):35-39.
24. Pinczewski LA, Lyman J, Salmon LJ, Russell VJ, Roe J, Linklater J. A 10-year comparison of anterior cruciate ligament reconstructions with hamstring tendon and patellar tendon autograft: a controlled, prospective trial. *Am J Sports Med*. 2007;35(4):564-574.
25. Rappe M, Horodyski M, Meister K, Indelicato PA. Nonirradiated versus irradiated Achilles allograft: in vivo failure comparison. *Am J Sports Med*. 2007;35(10):1653-1658.
26. Rasmussen TJ, Feder SM, Butler DL, Noyes FR. The effects of 4 Mrad of gamma irradiation on the initial mechanical properties of bone-patellar tendon-bone grafts. *Arthroscopy*. 1994;10(2):188-197.
27. Rihn JA, Irrgang JJ, Chhabra A, Fu FH, Harner CD. Does irradiation affect the clinical outcome of patellar tendon allograft ACL reconstruction? *Knee Surg Sports Traumatol Arthrosc*. 2006;14(9):885-896.
28. Rodeo SA, Arnoczky SP, Torzilli PA, Hidaka C, Warren RF. Tendon-healing in a bone tunnel: a biomechanical and histological study in the dog. *J Bone Joint Surg Am*. 1993;75(12):1795-1803.
29. Rodeo SA, Kawamura S, Kim HJ, Dinybil C, Ying L. Tendon healing in a bone tunnel differs at the tunnel entrance versus the tunnel exit: an effect of graft-tunnel motion? *Am J Sports Med*. 2006;34(11):1790-1800.
30. Rodeo SA, Kawamura S, Ma CB, et al. The effect of osteoclastic activity on tendon-to-bone healing: an experimental study in rabbits. *J Bone Joint Surg Am*. 2007;89(10):2250-2259.
31. Schwartz HE, Matava MJ, Proch FS, et al. The effect of gamma irradiation on anterior cruciate ligament allograft biomechanical and biochemical properties in the caprine model at time zero and at 6 months after surgery. *Am J Sports Med*. 2006;34(11):1747-1755.
32. Shelton WR, Treacy SH, Dukes AD, Bomboy AL. Use of allografts in knee reconstruction, II: surgical considerations. *J Am Acad Orthop Surg*. 1998;6(3):169-175.
33. Simonds RJ, Holmberg SD, Hurwitz RL, et al. Transmission of human immunodeficiency virus type 1 from a seronegative organ and tissue donor. *N Engl J Med*. 1992;326(11):726-732.
34. Stevenson S. Biology of bone grafts. *Orthop Clin North Am*. 1999;30(4):543-552.
35. Sun K, Tian S, Zhang J, Xia C, Zhang C, Yu T. Anterior cruciate ligament reconstruction with BPTB autograft, irradiated versus non-irradiated allograft: a prospective randomized clinical study. *Knee Surg Sports Traumatol Arthrosc*. 2009;17(5):464-474.
36. Sun K, Zhang J, Wang Y, et al. Arthroscopic anterior cruciate ligament reconstruction with at least 2.5 years' follow-up comparing hamstring tendon autograft and irradiated allograft. *Arthroscopy*. 2011;27(9):1195-1202.
37. Sun K, Zhang J, Wang Y, et al. A prospective randomized comparison of irradiated and non-irradiated hamstring tendon allograft for ACL reconstruction. *Knee Surg Sports Traumatol Arthrosc*. Feb 3 2011. [Epub ahead of print] DOI: 10.1007/s00167-010-1393-9.
38. Vangsness CT Jr, Triffon MJ, Joyce MJ, Moore TM. Soft tissue for allograft reconstruction of the human knee: a survey of the American Association of Tissue Banks. *Am J Sports Med*. 1996;24(2):230-234.

---

For reprints and permission queries, please visit SAGE's Web site at <http://www.sagepub.com/journalsPermissions.nav>